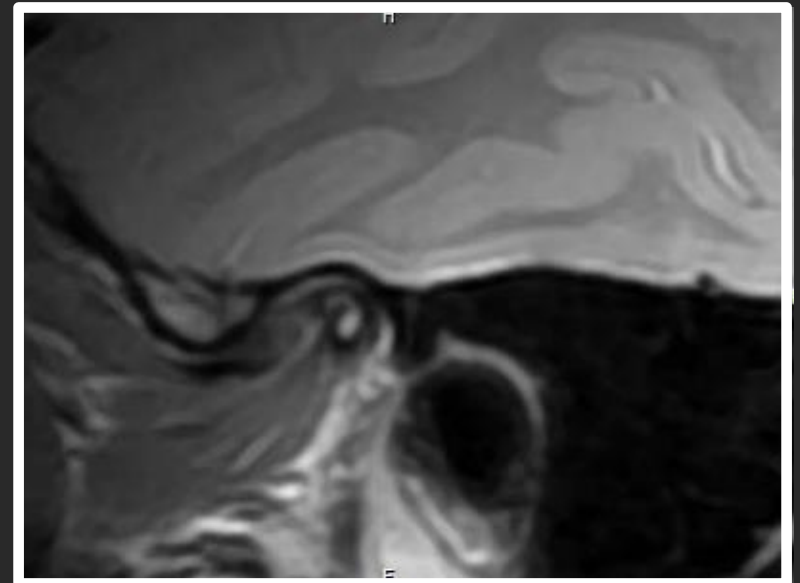
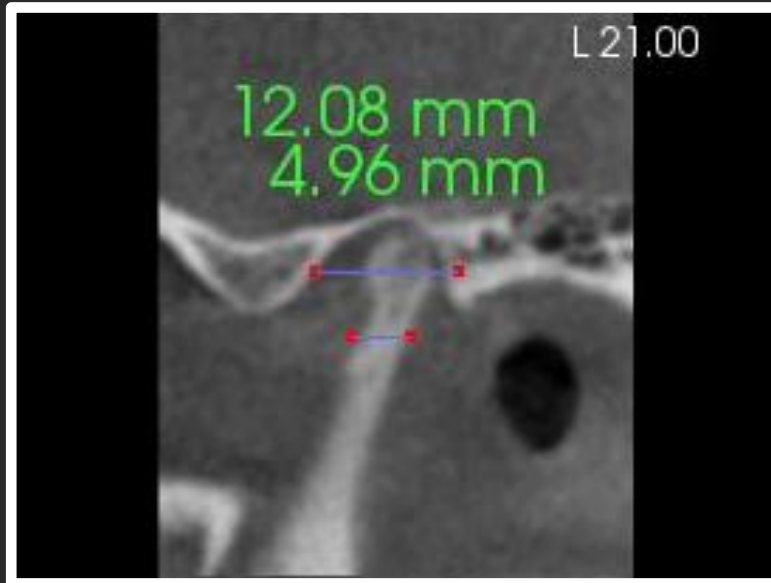
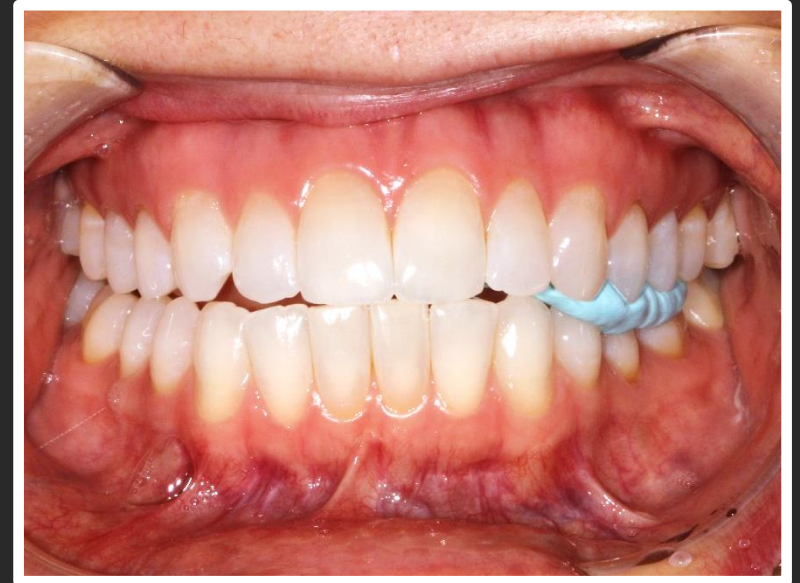
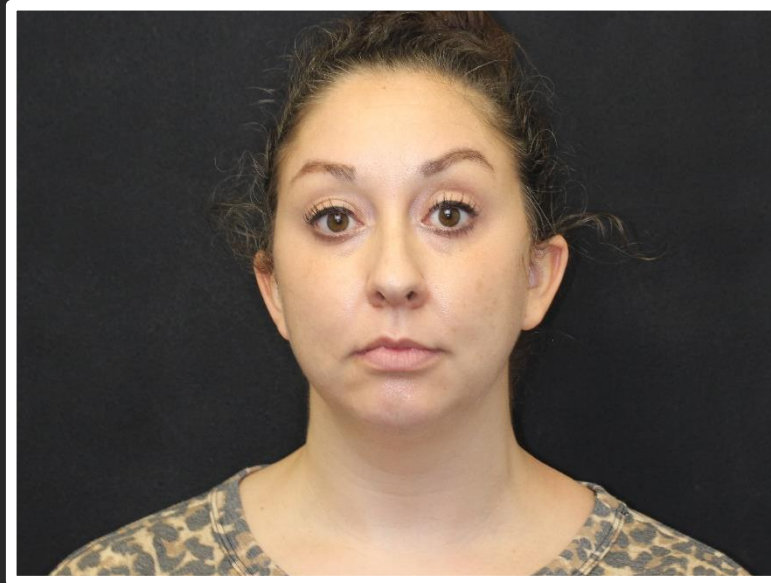


Piper Clinic Case Presentation

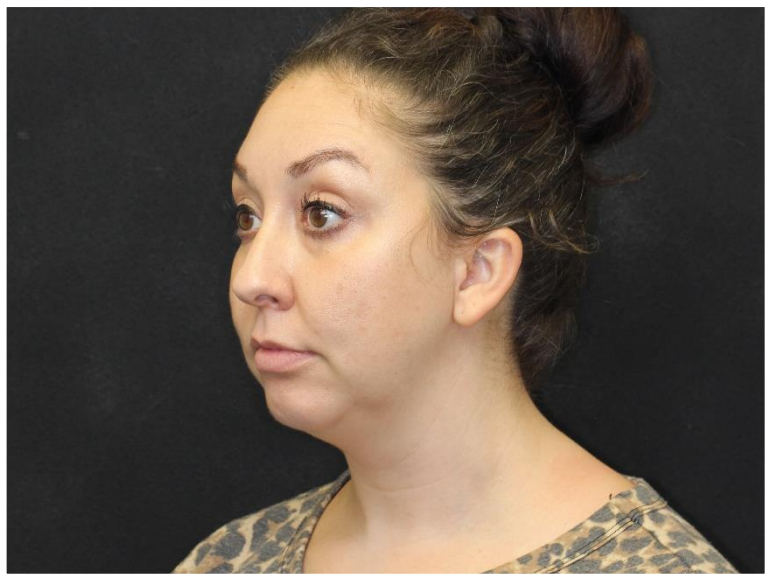
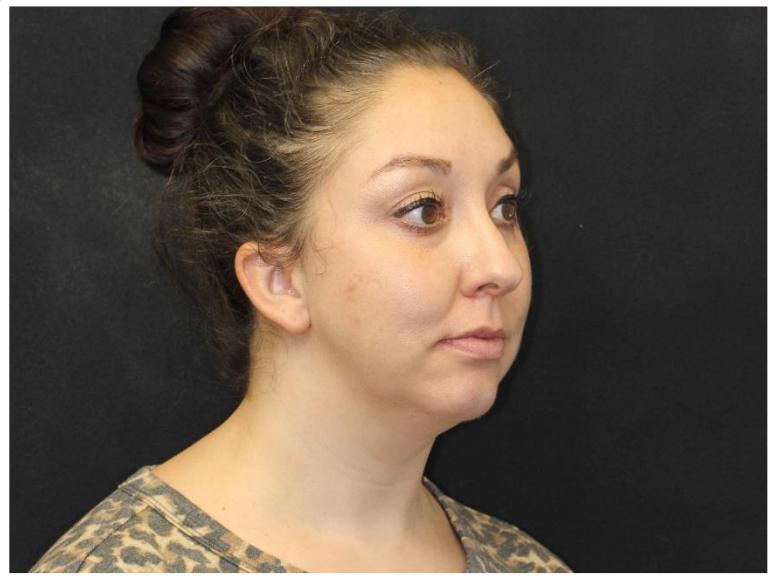
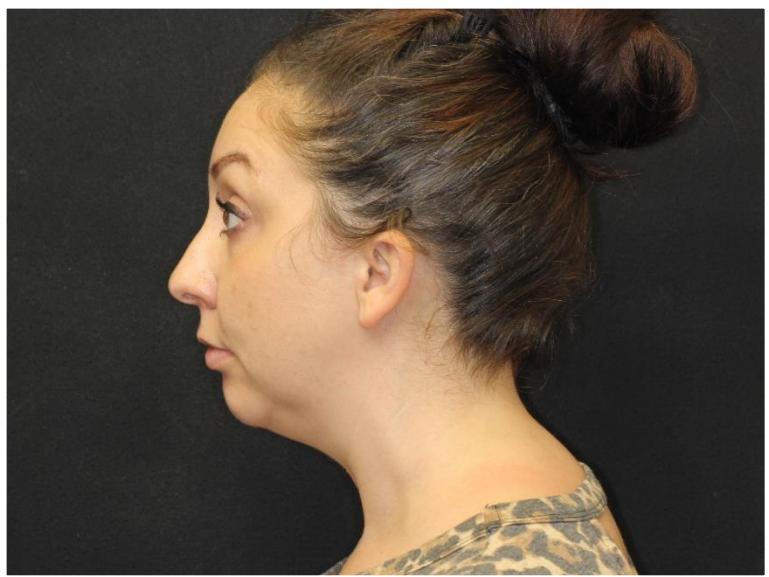
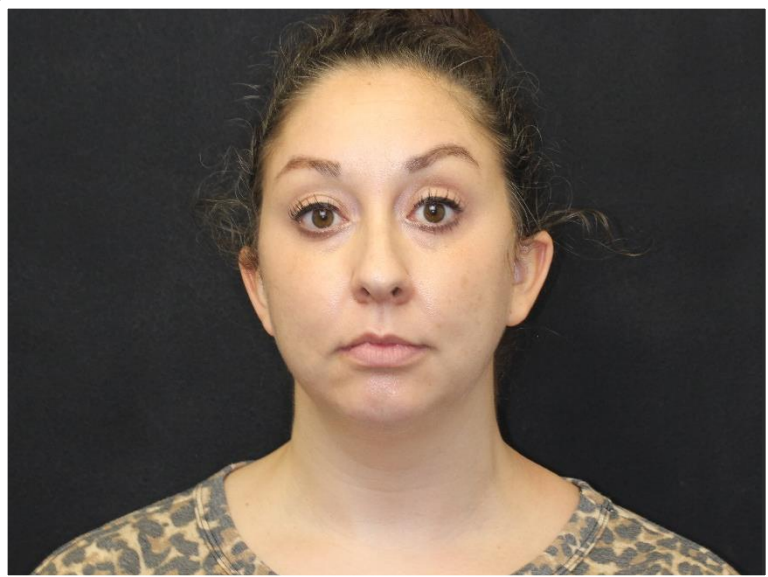
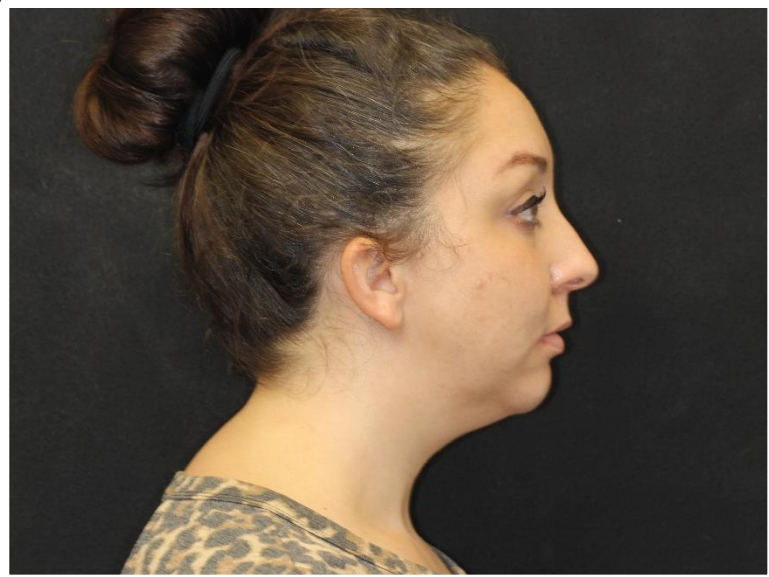Patient: Dr. Anna Minnema



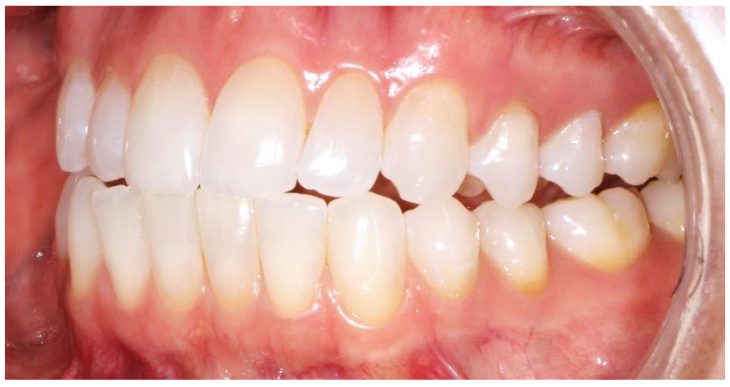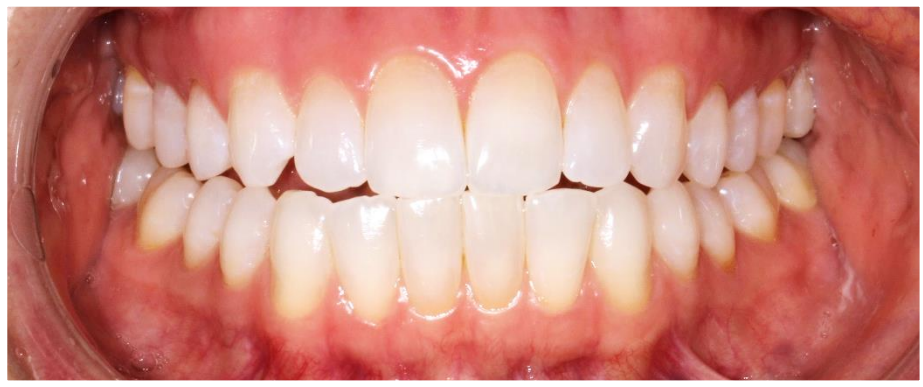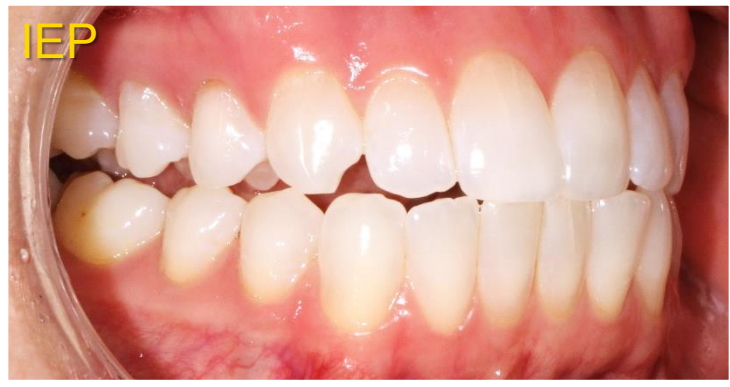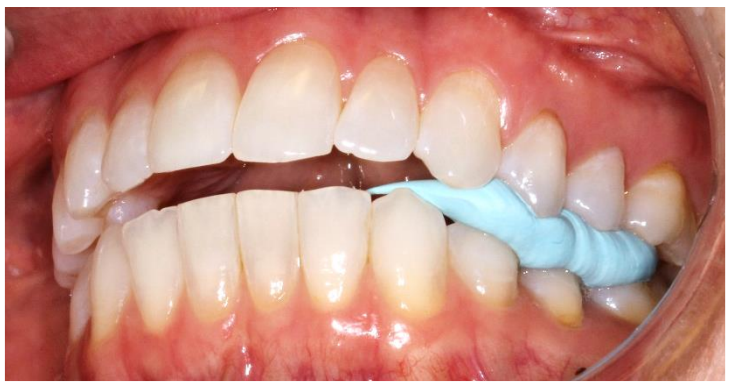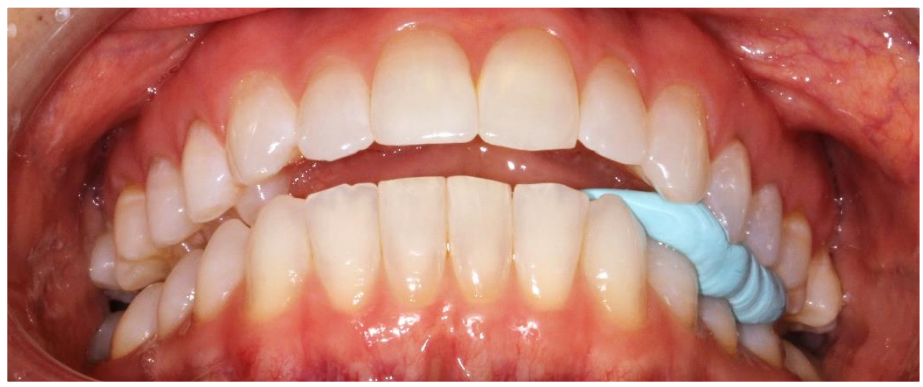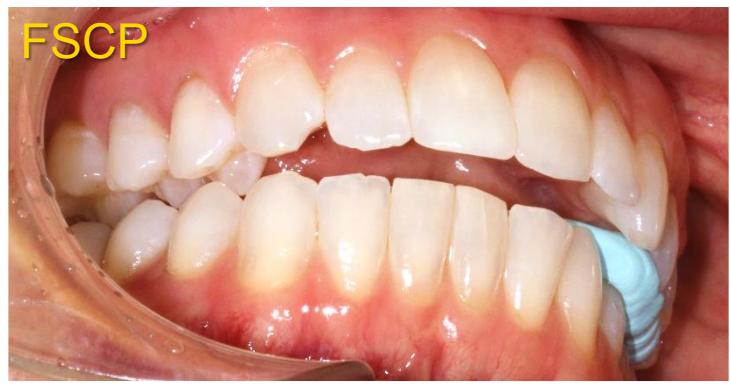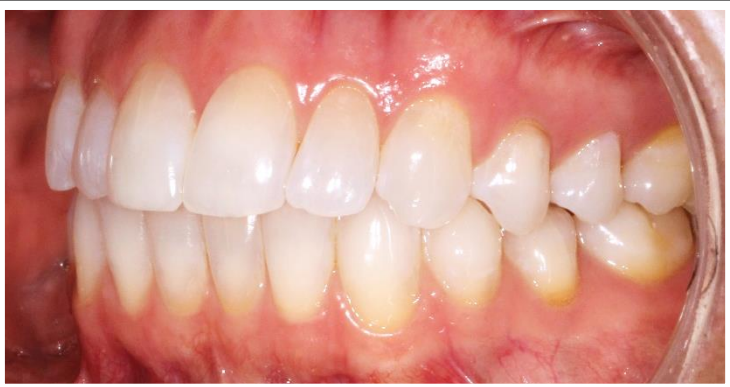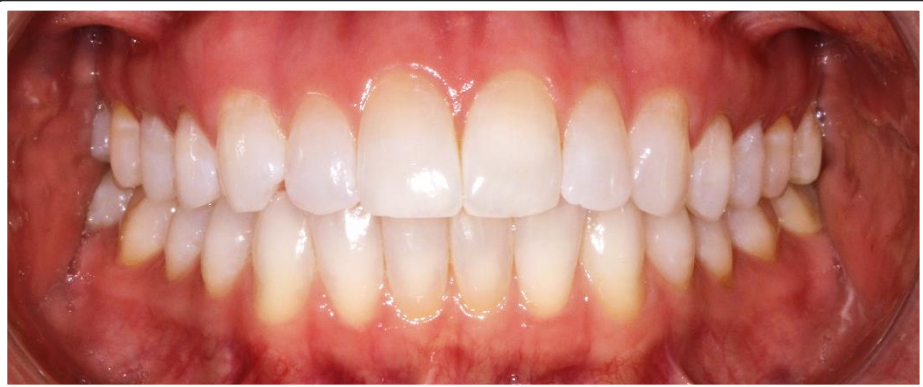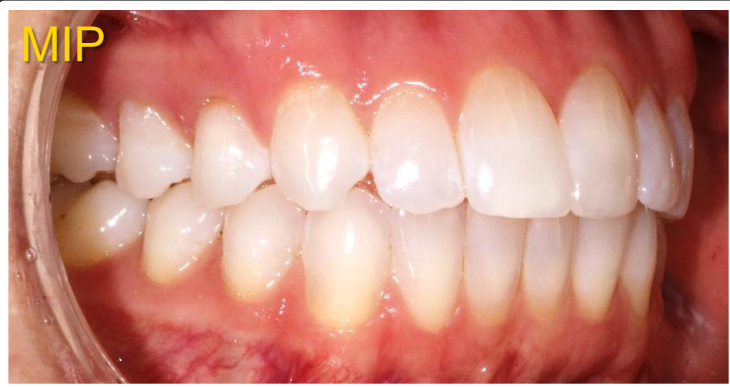Evaluation Date: 03/08/2022



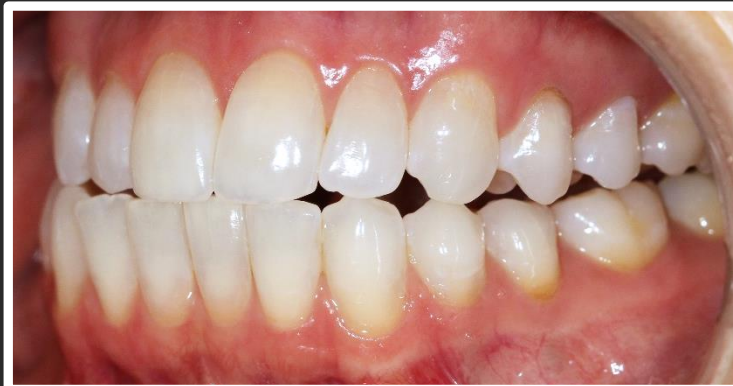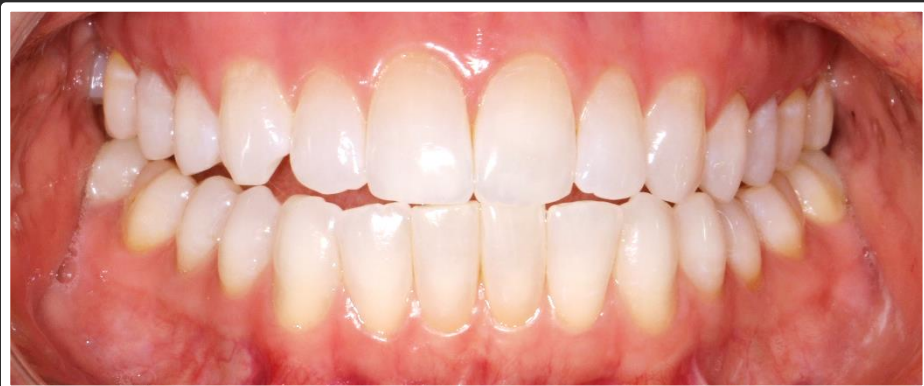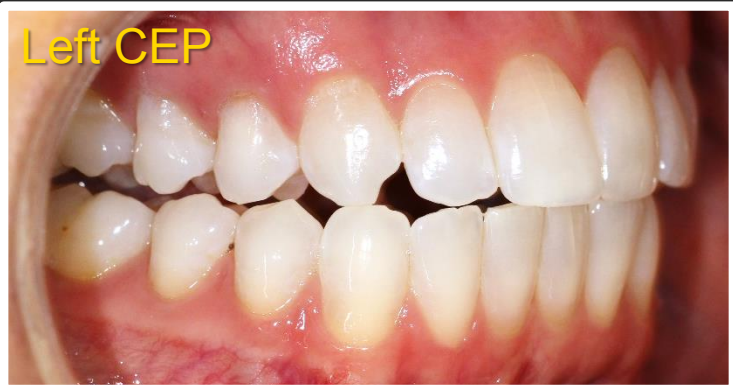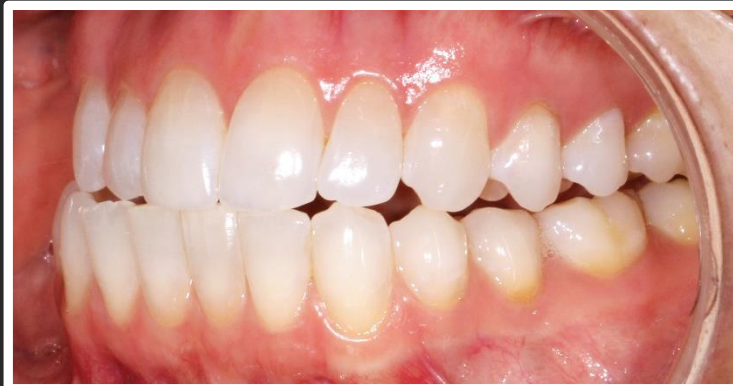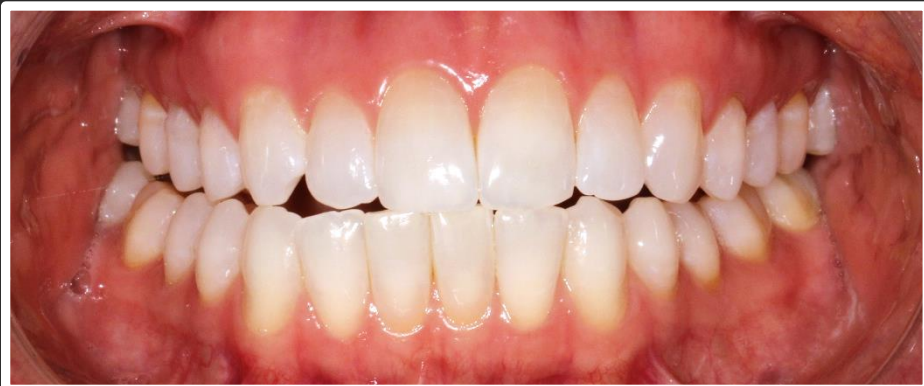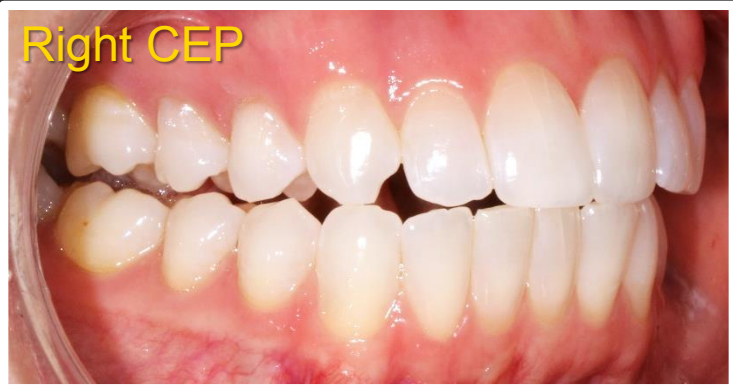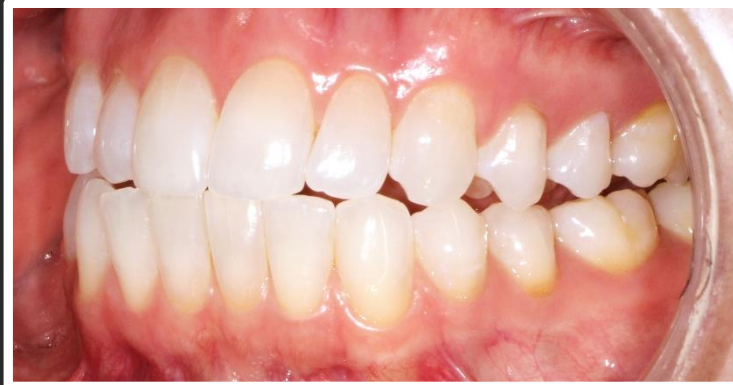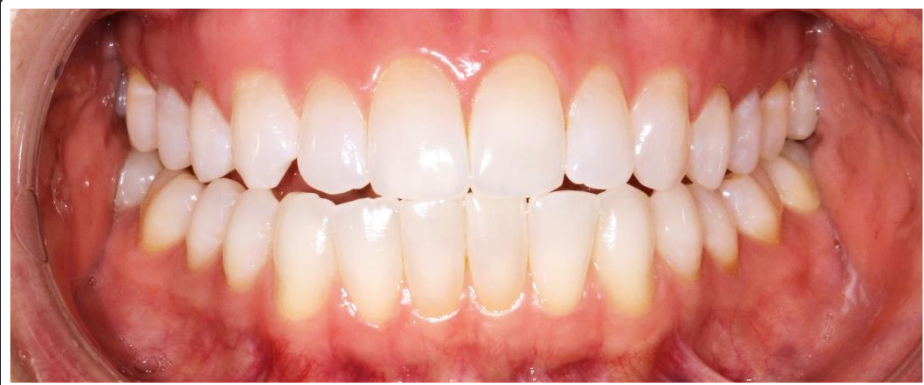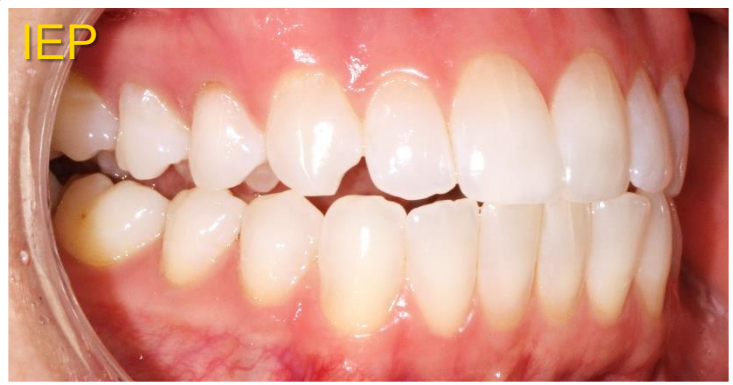Initial Evaluation Facial and Cervical: Anna Minnema 03/08/2022



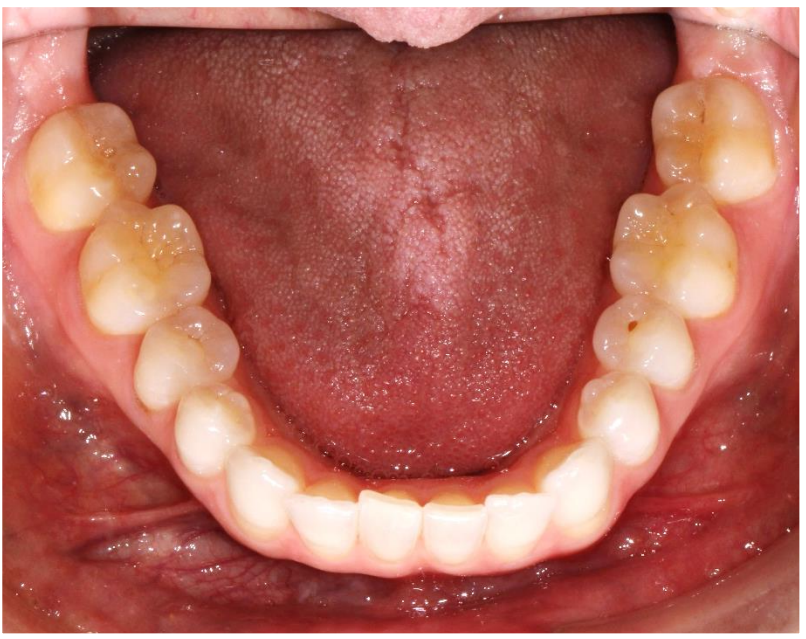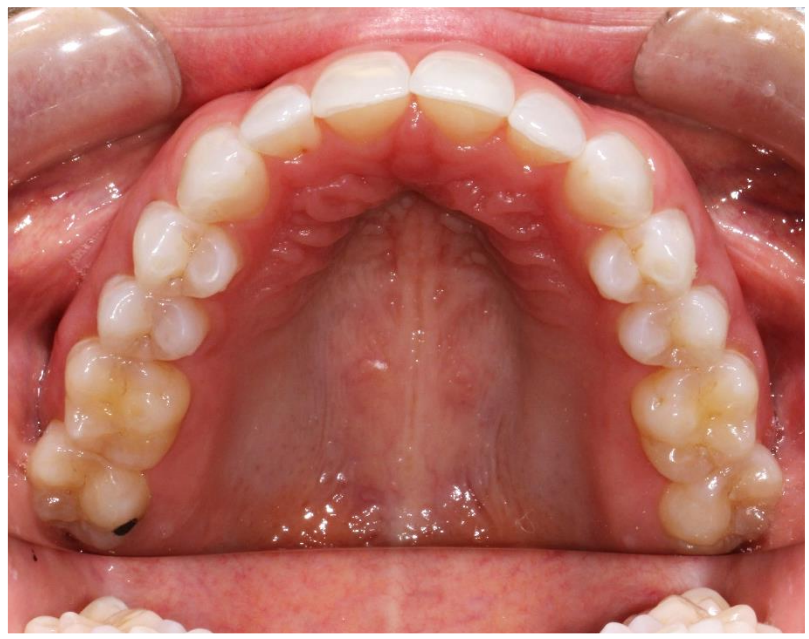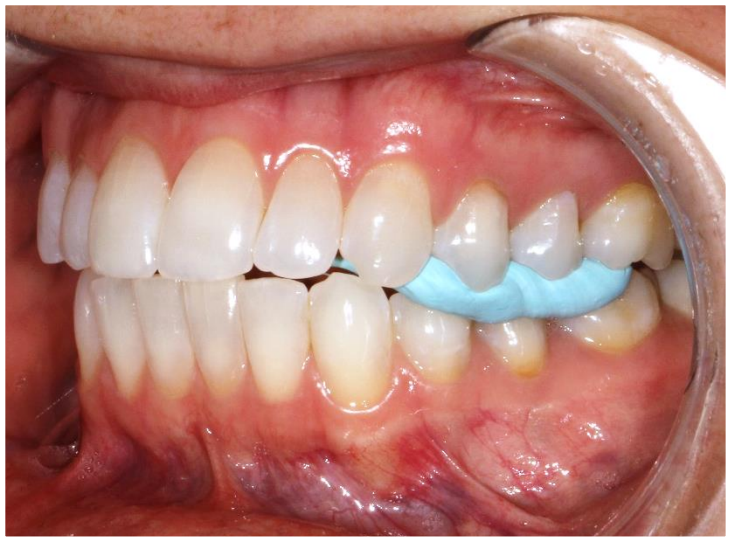
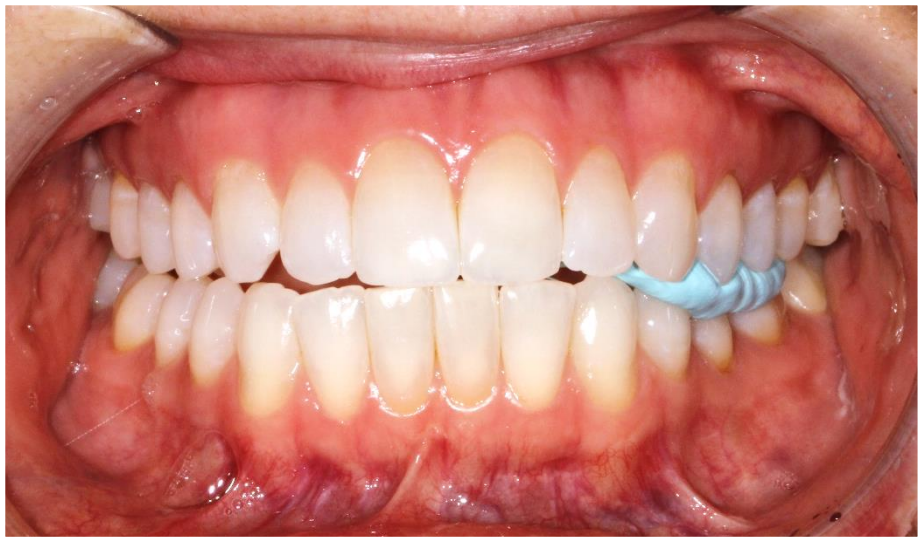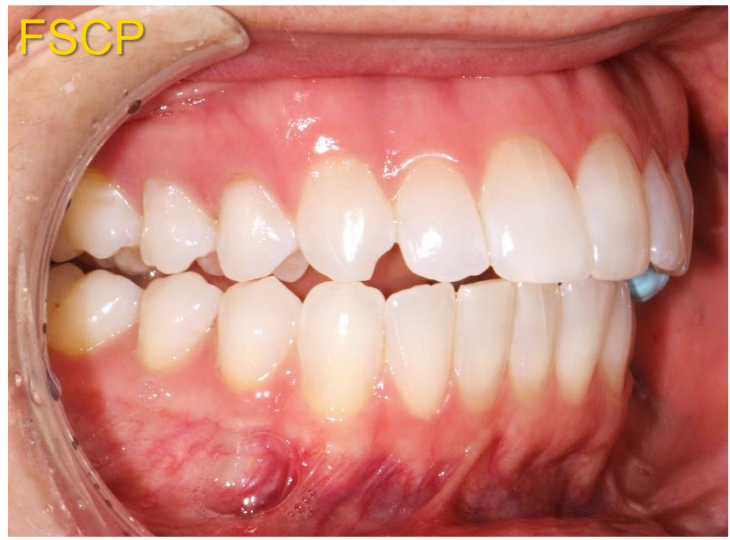Initial Evaluation Occlusion: Anna Minnema 03/08/2022



Initial Evaluation Functional Occlusion: Anna Minnema 03/08/2022

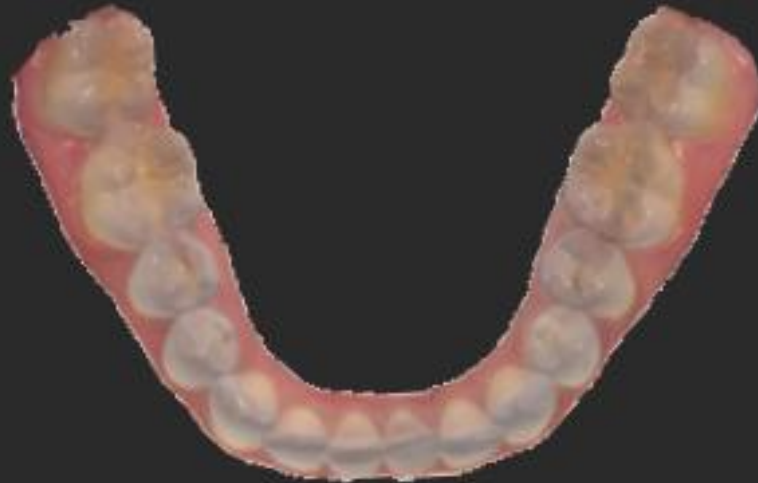
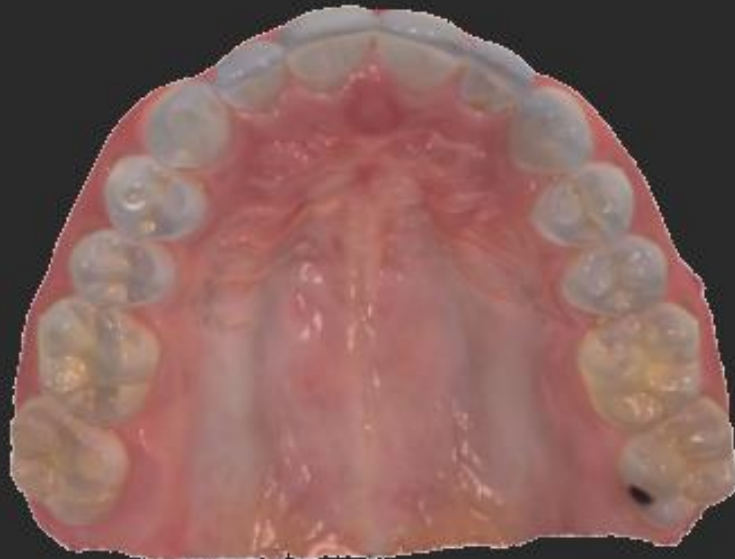
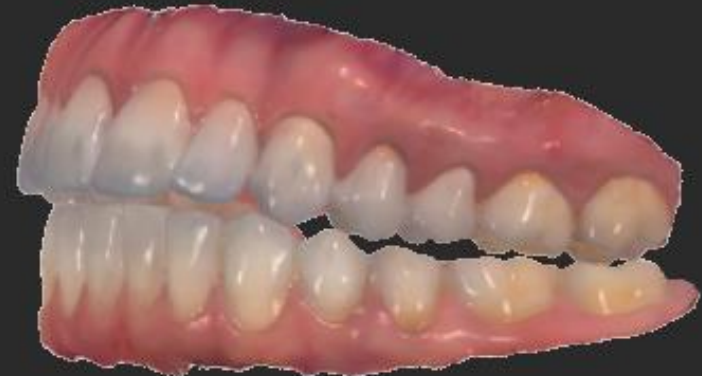
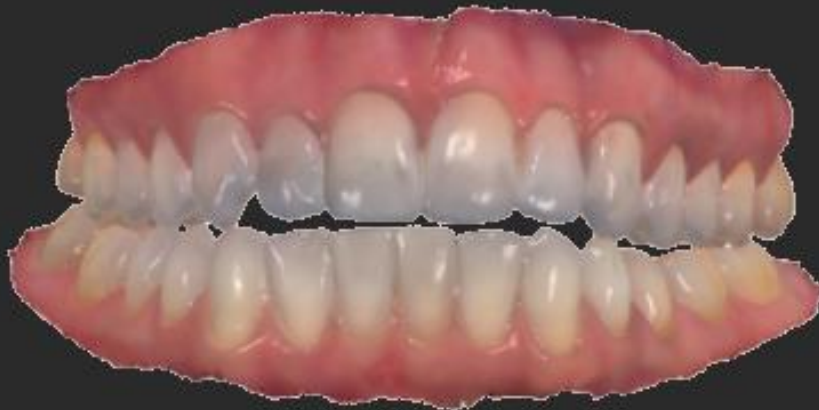
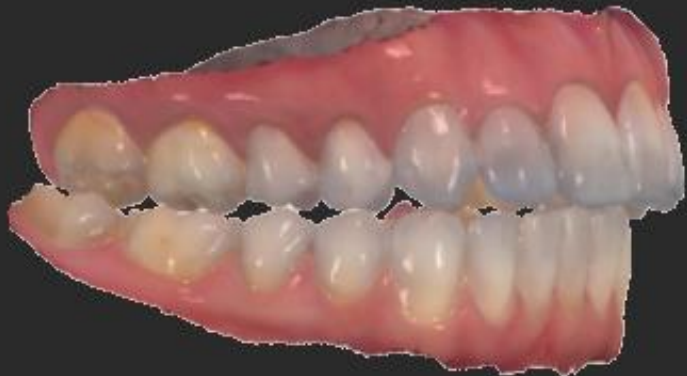Initial Evaluation Occlusion FSCP: Anna Minnema 03/08/2022

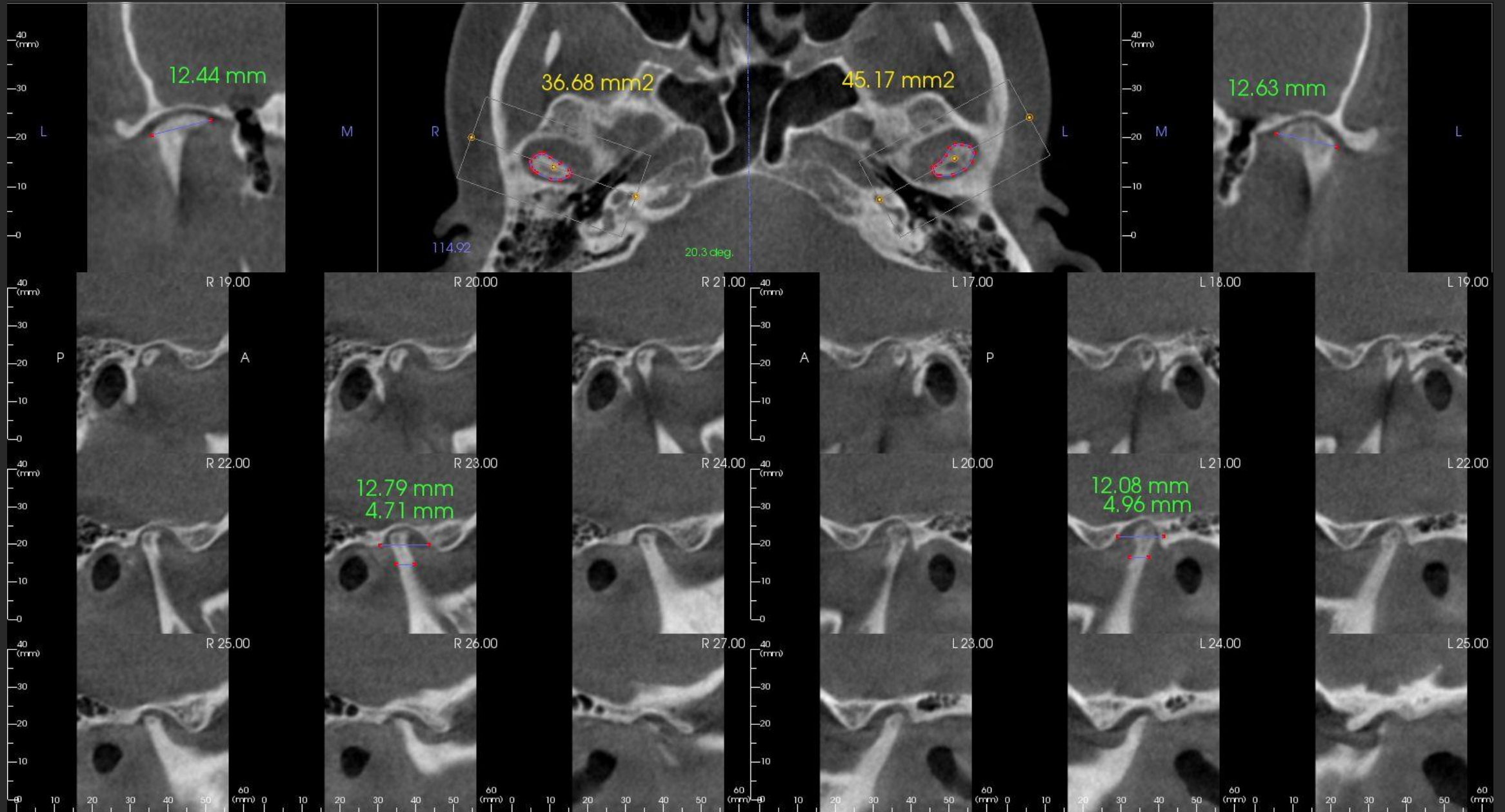


Initial Evaluation Trios Study Models FSCP: Anna Minnema 03/08/2022

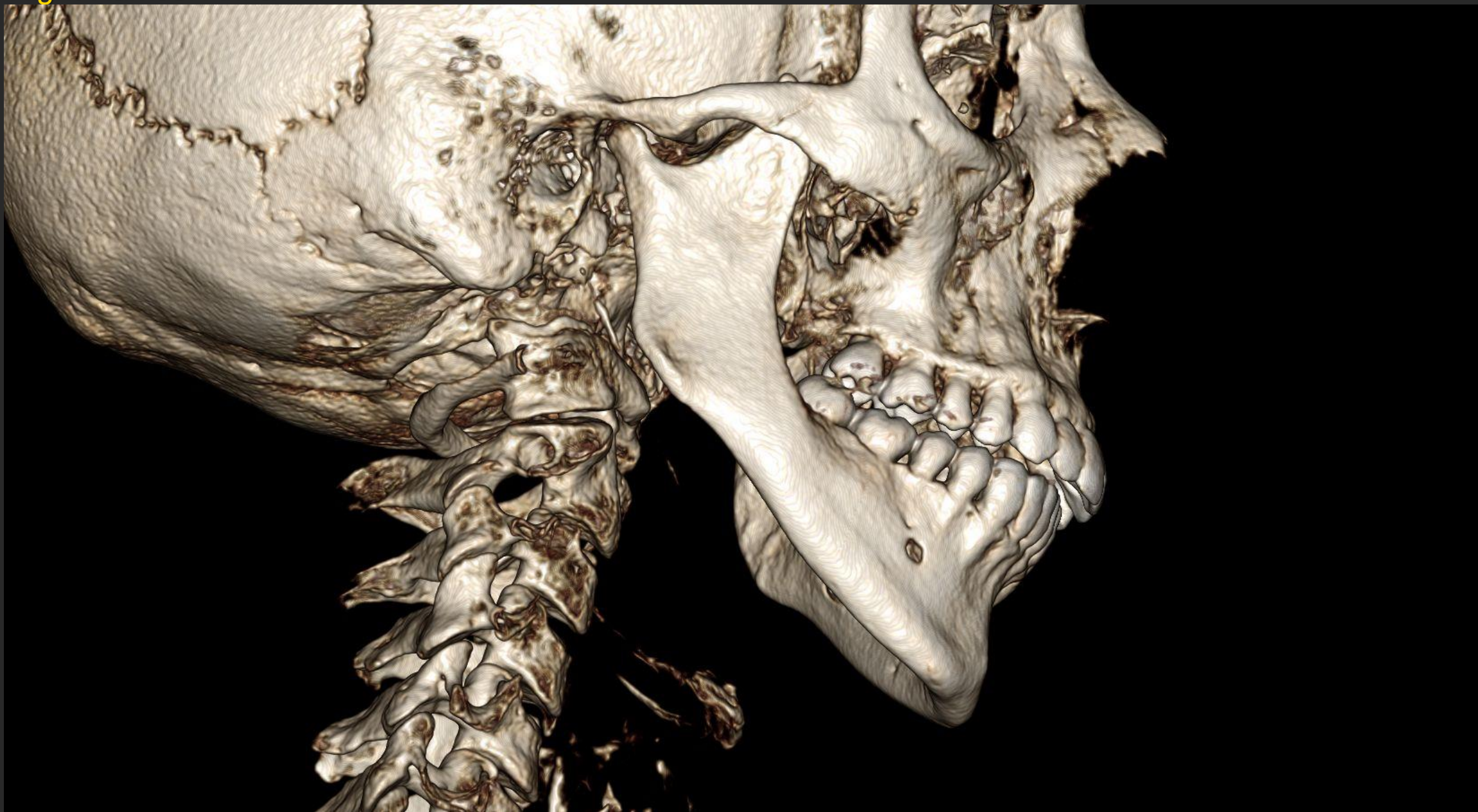
FSCP



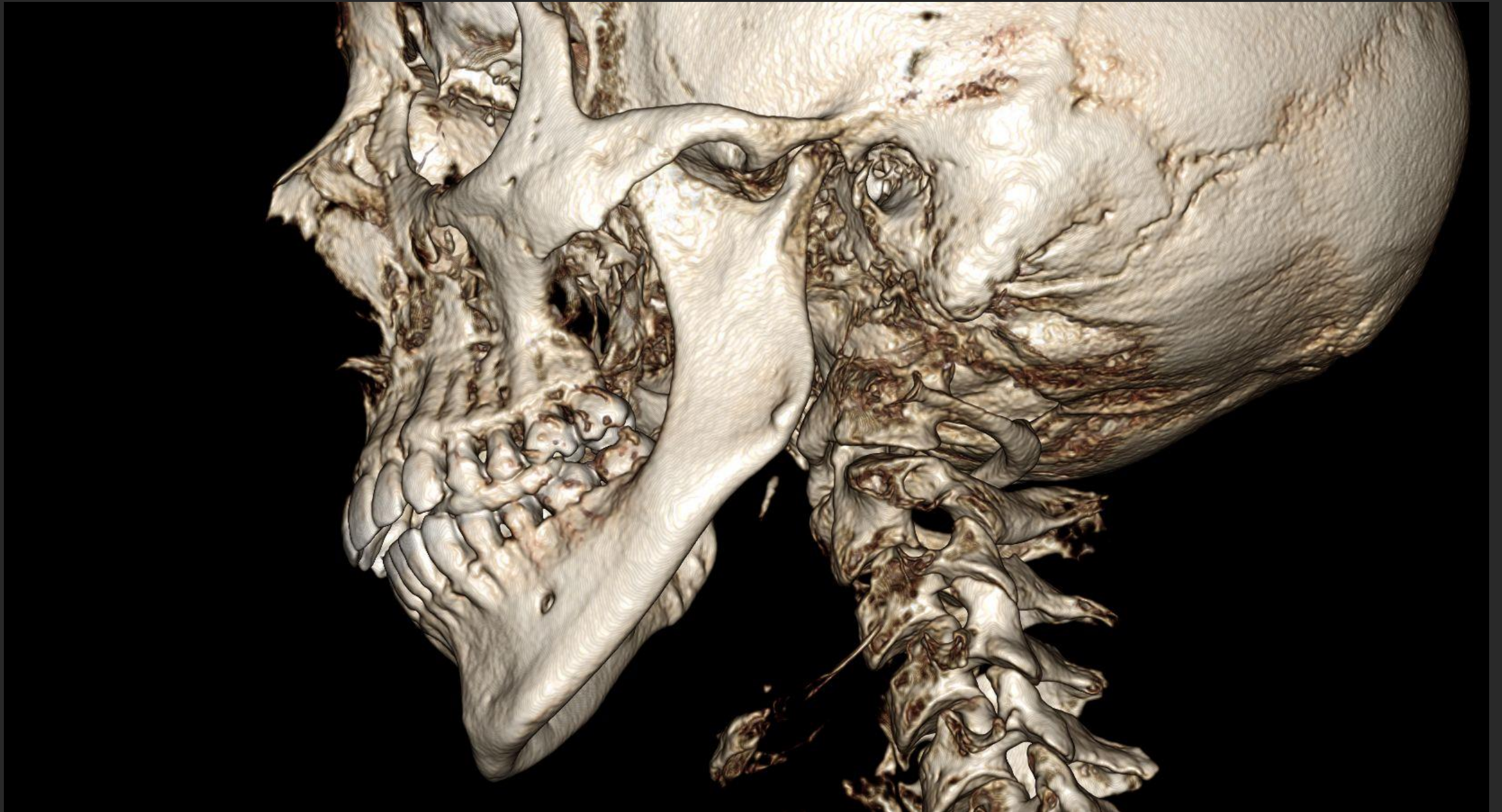
2D TMJ: Anna Minnema 03/08/2022



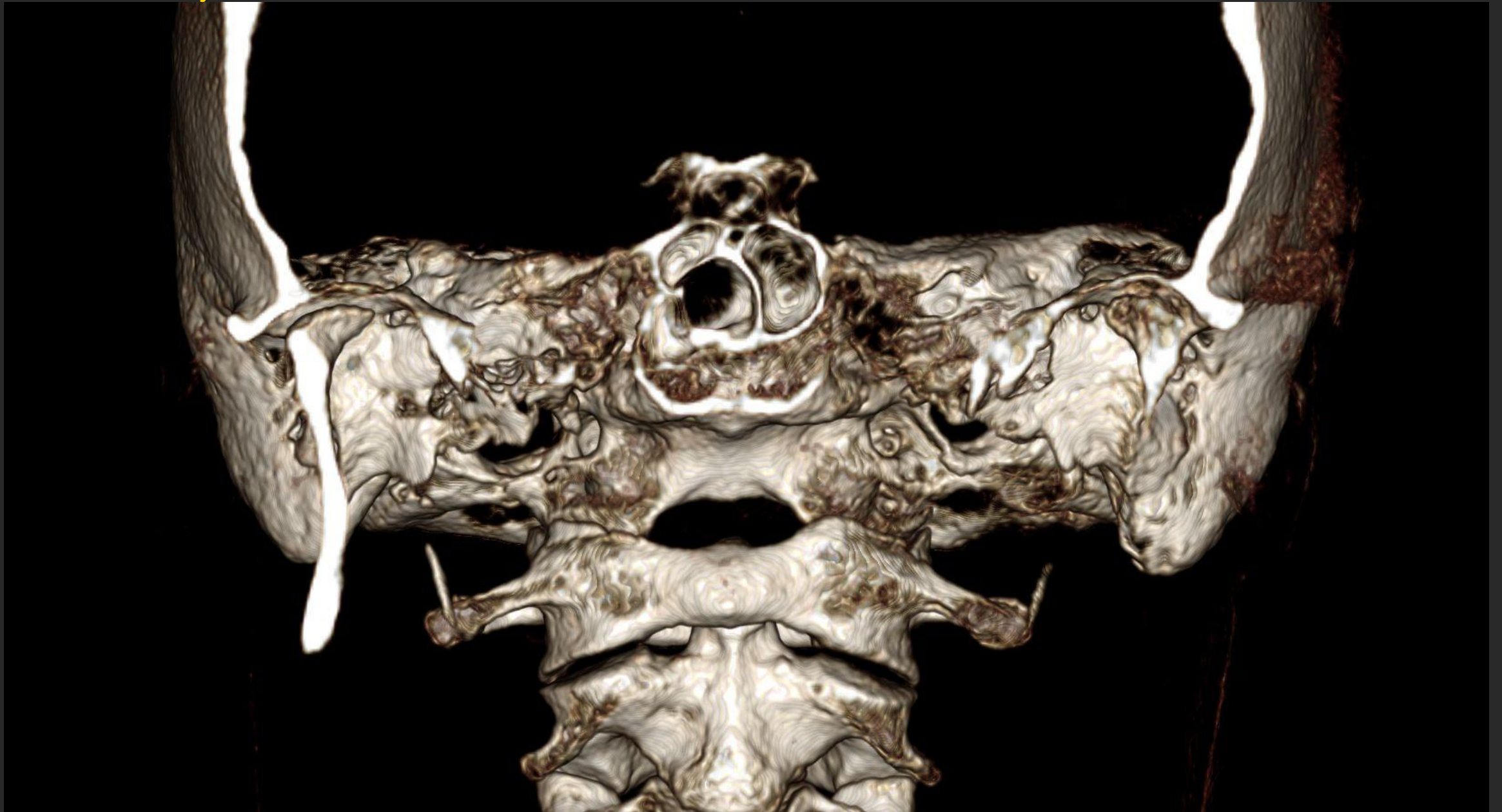Right Ramus: Anna Minnema 03/08/2022

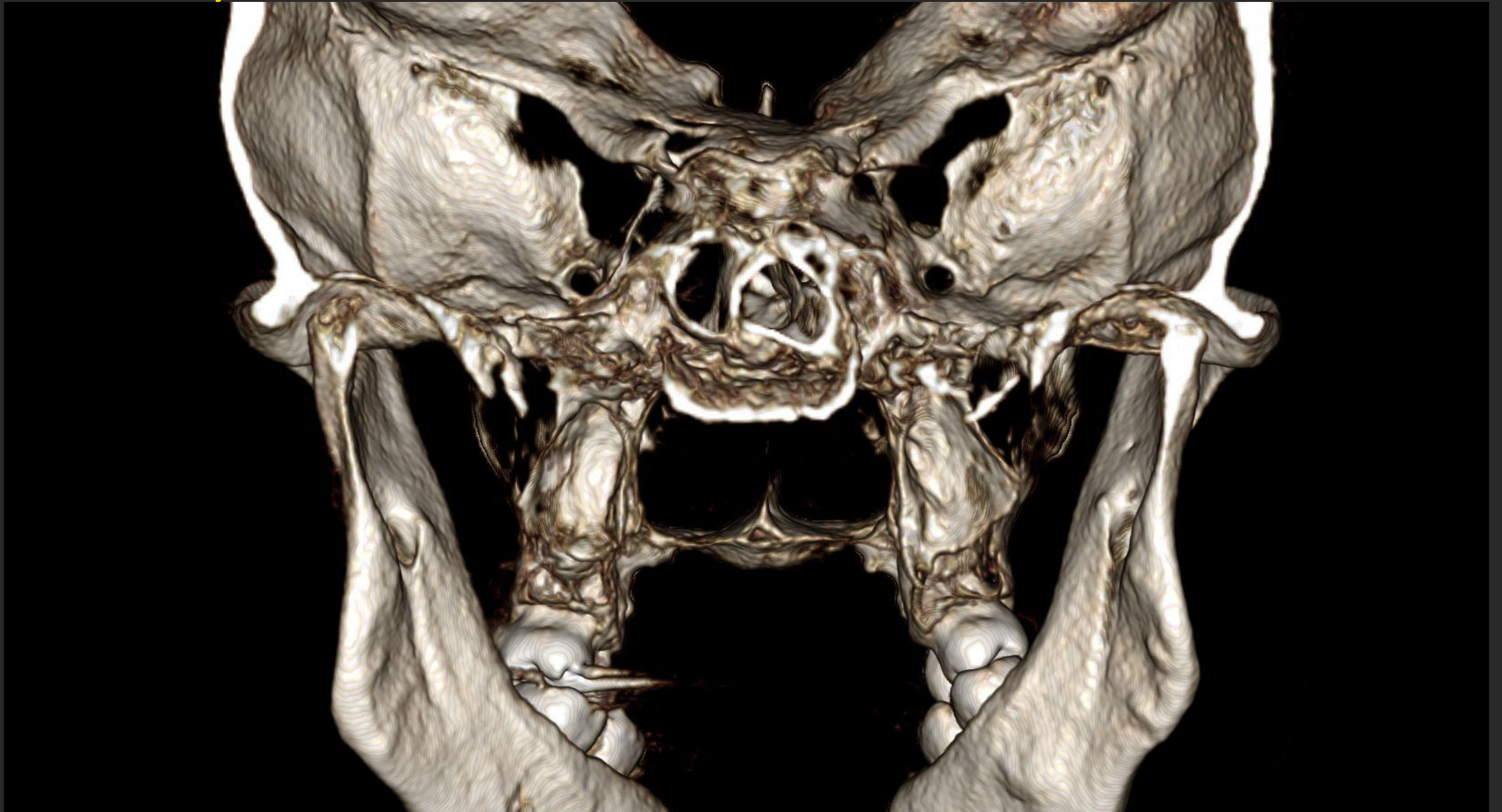


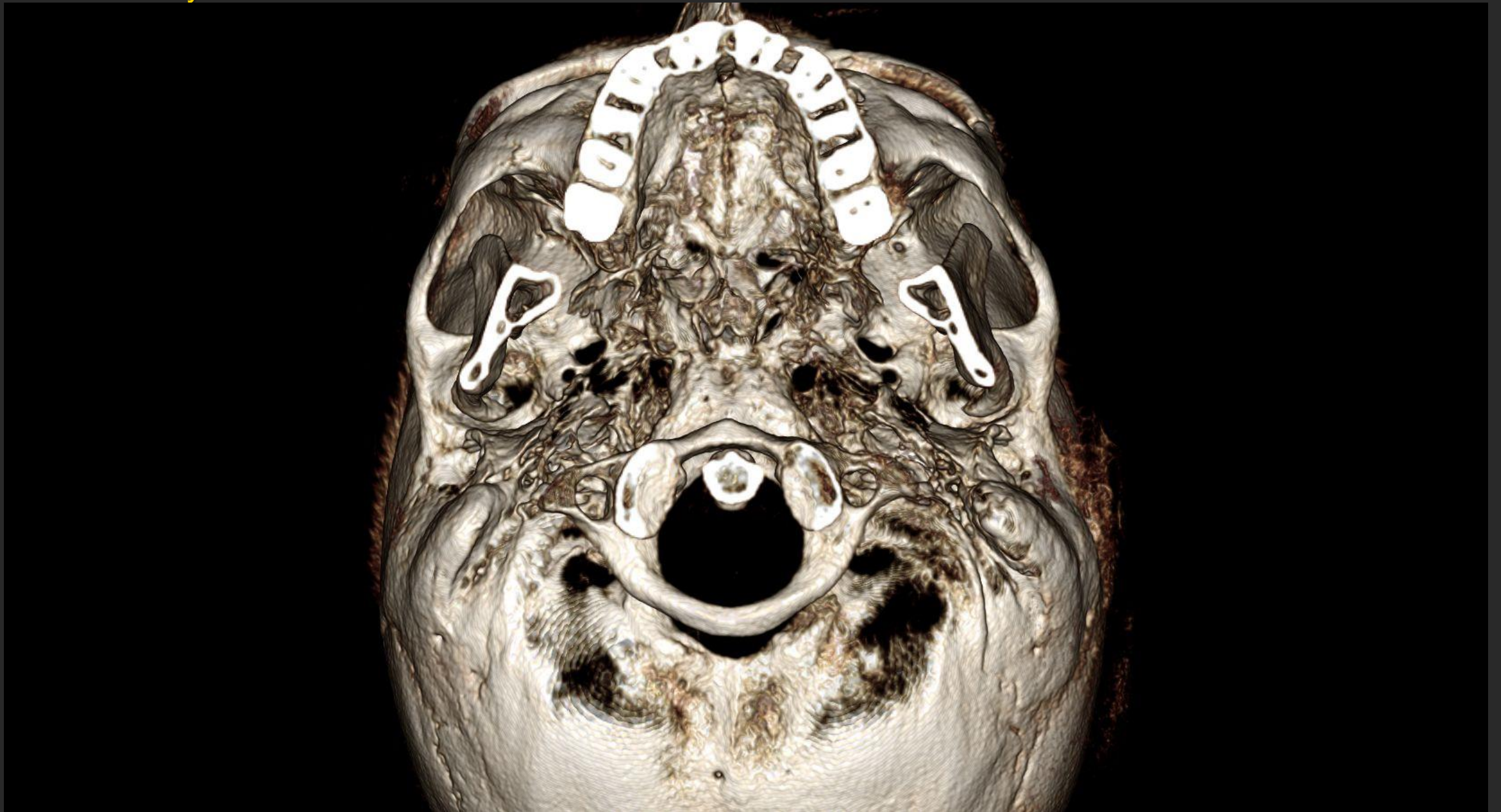Left Ramus: Anna Minnema 03/08/2022



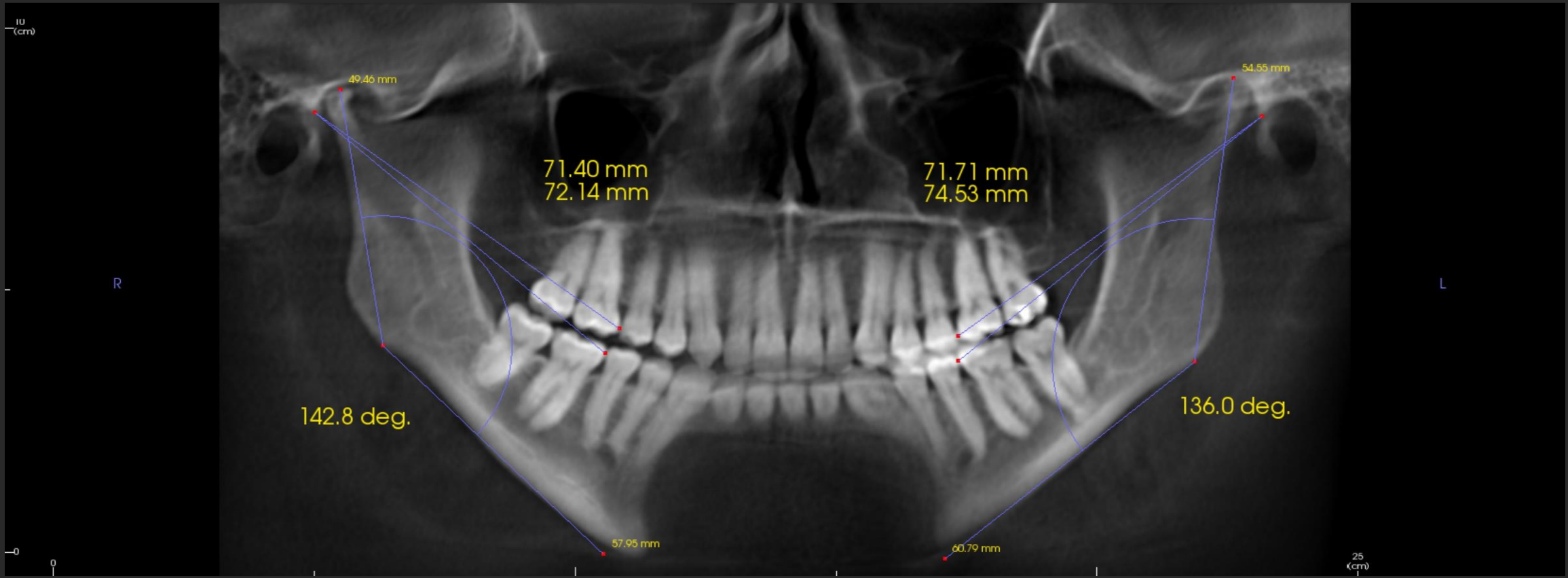
Anterior Condyles: Anna Minnema 03/08/2022



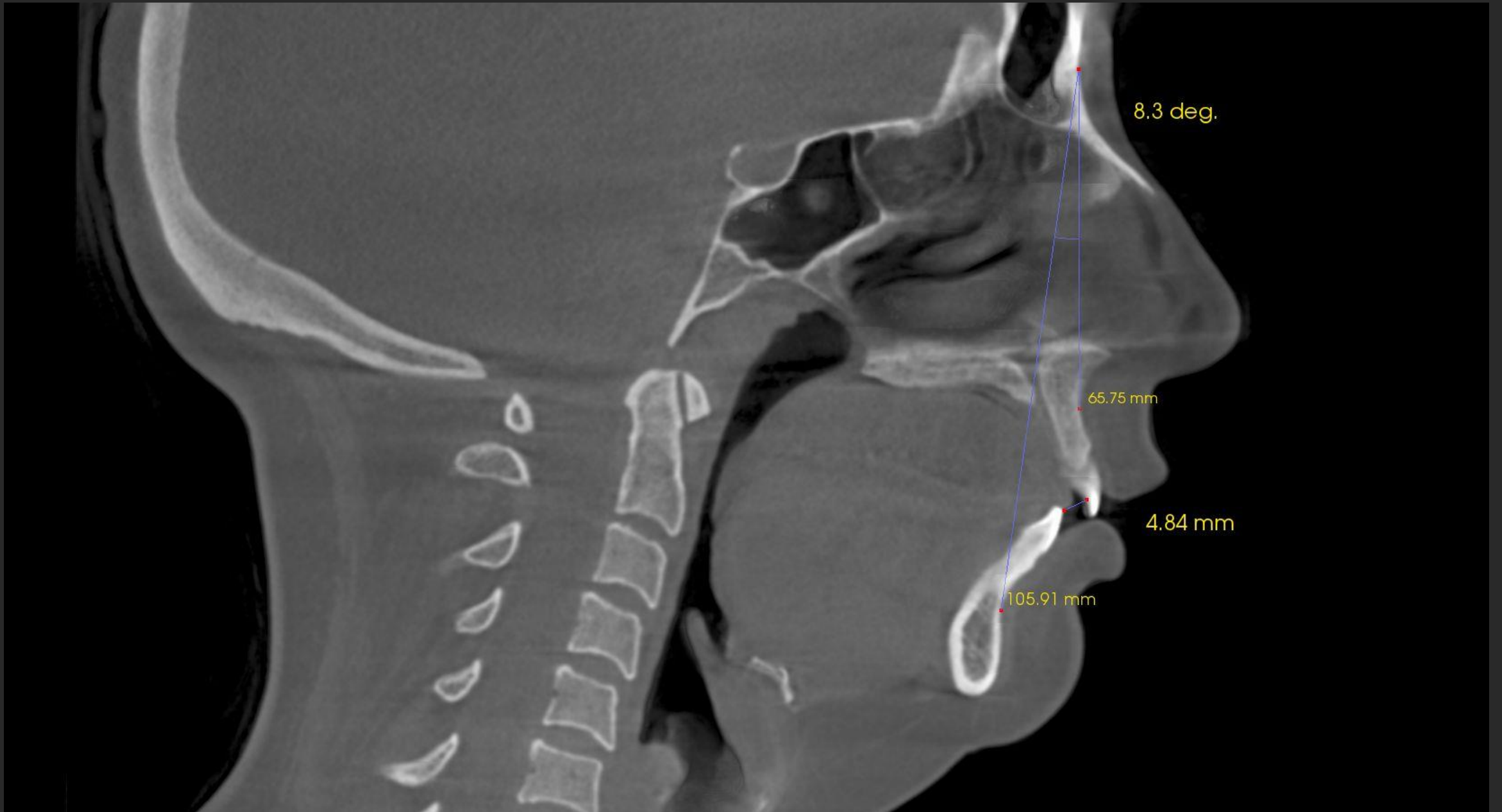




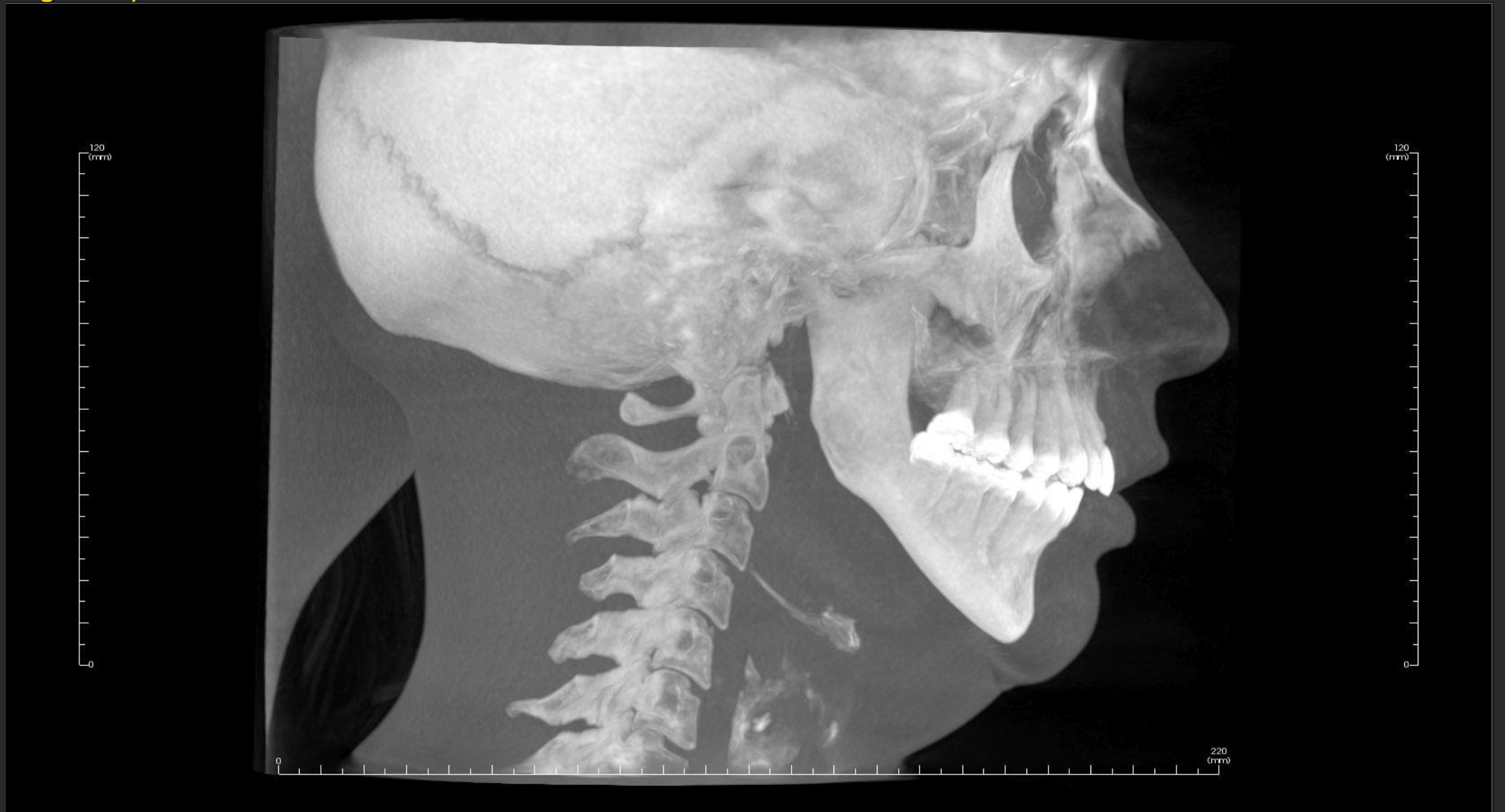
Panorex: Anna Minnema 03/08/2022



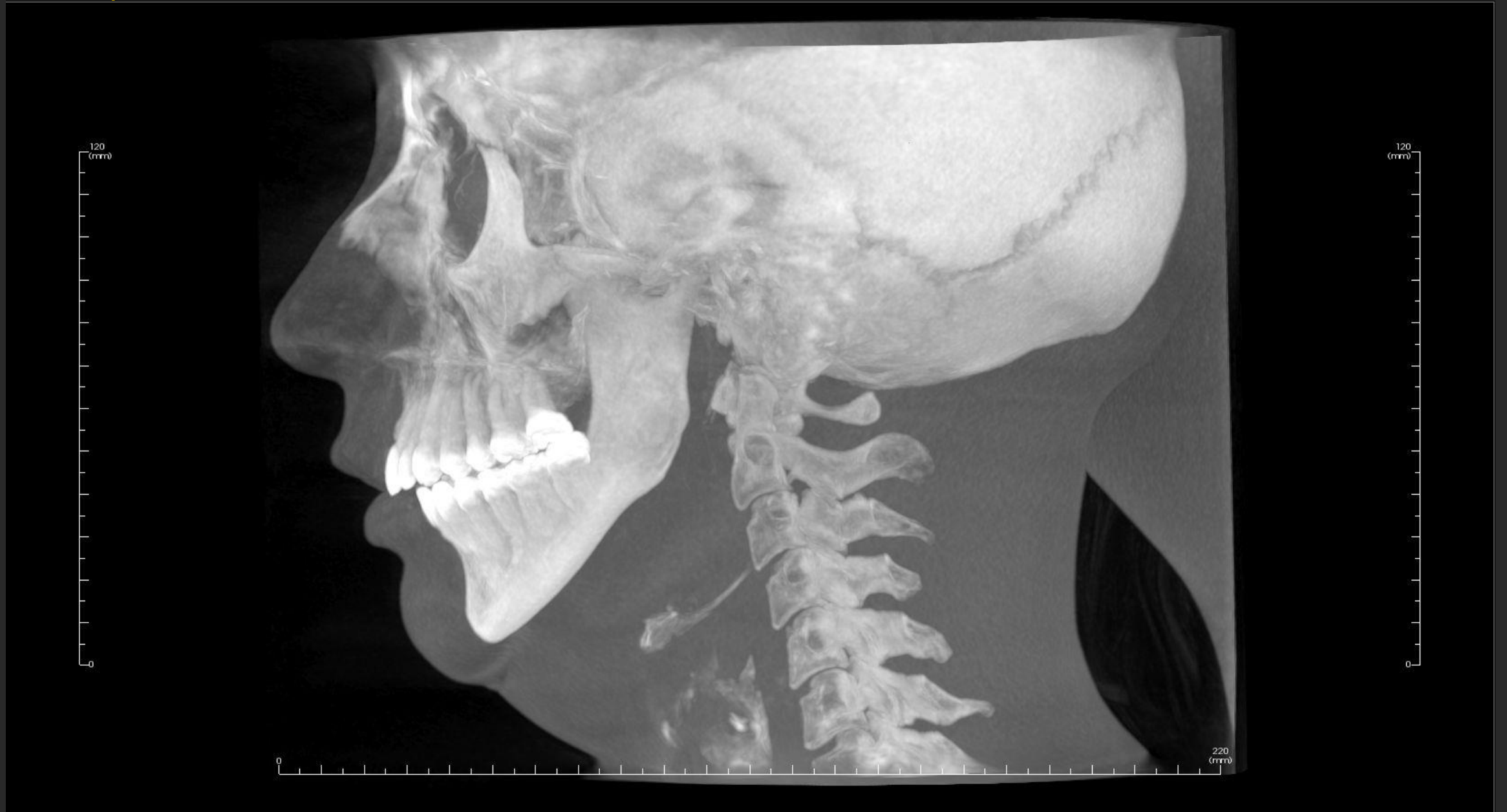
Midline Profile: Anna Minnema 03/08/2022



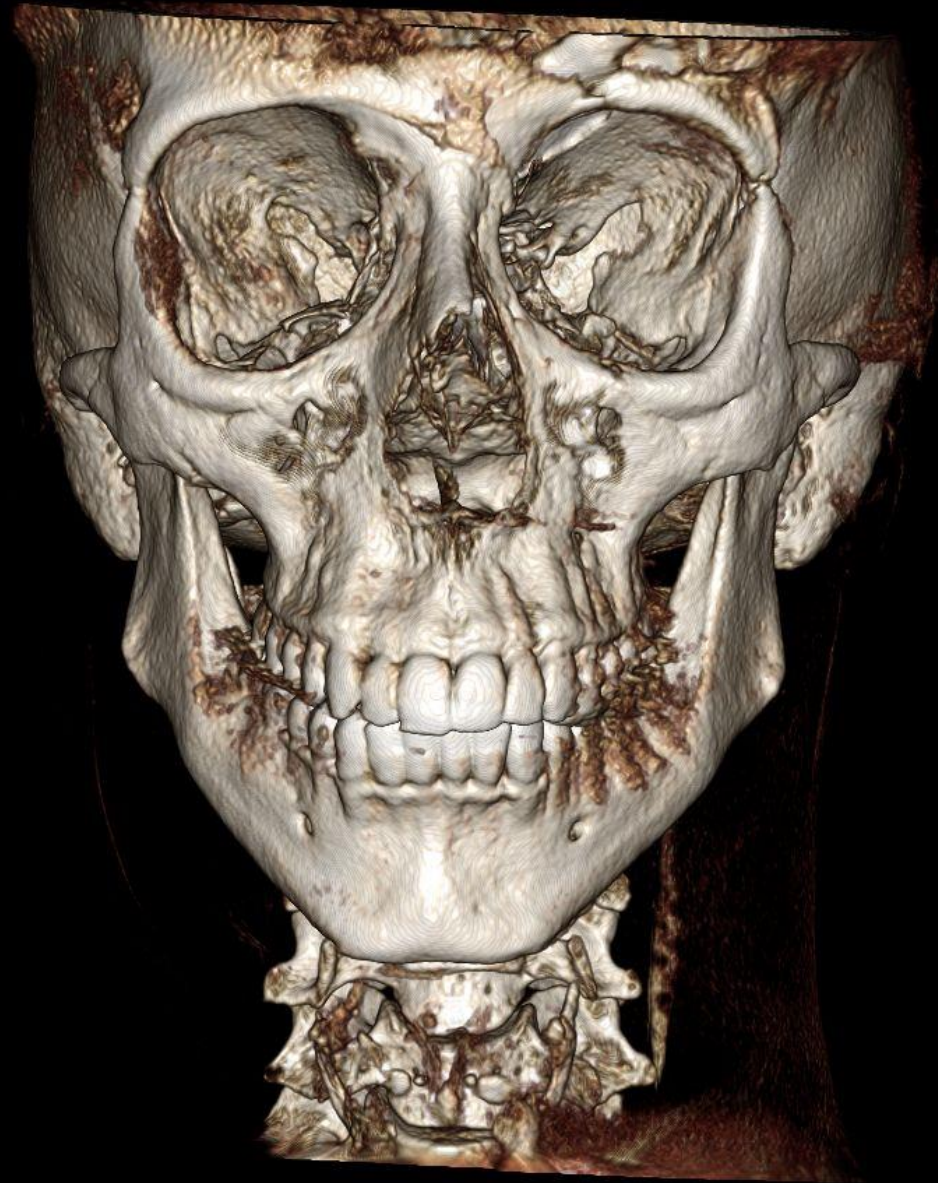Right Ceph: Anna Minnema 03/08/2022

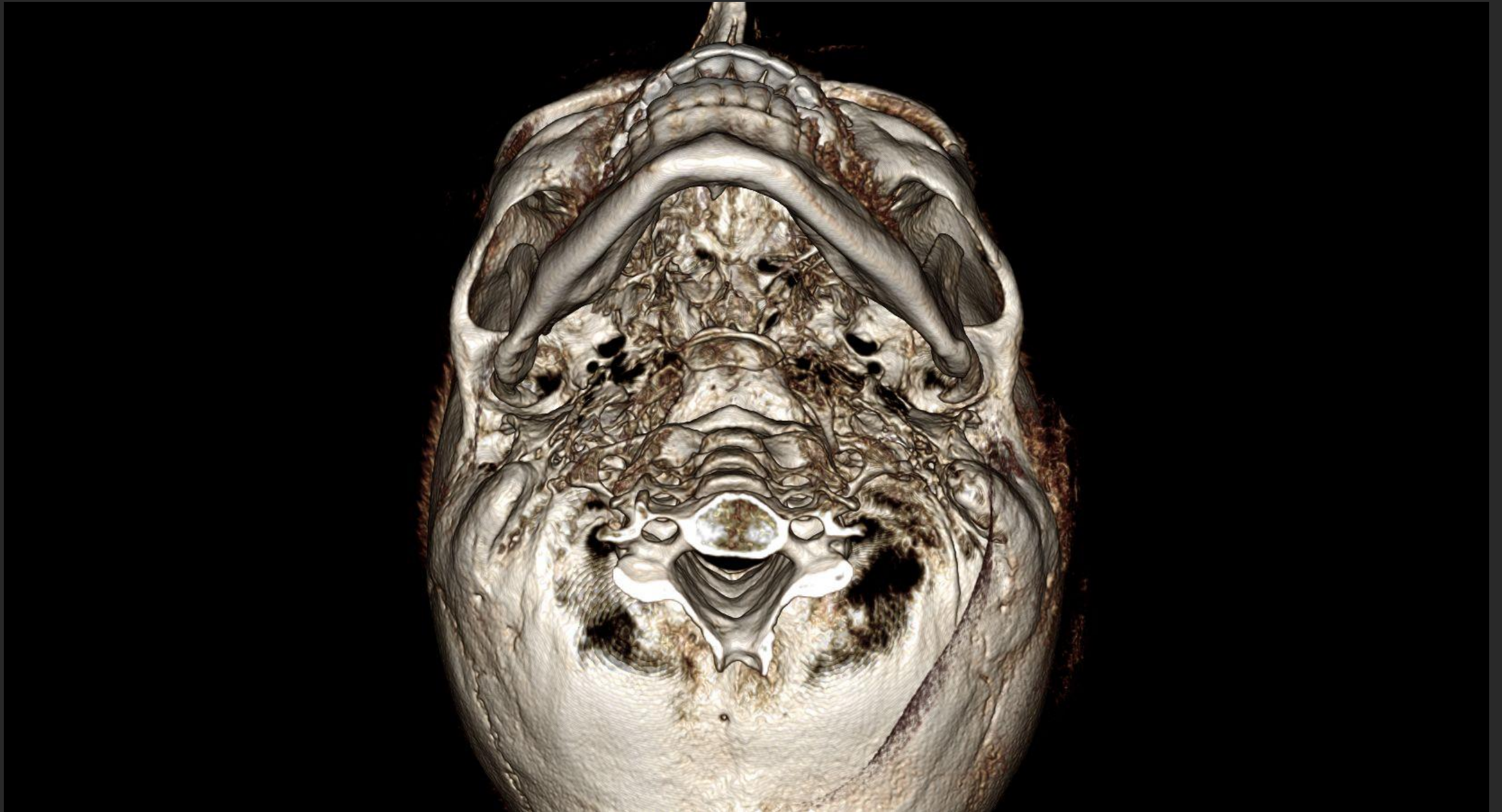


Left Ceph: Anna Minnema 03/08/2022

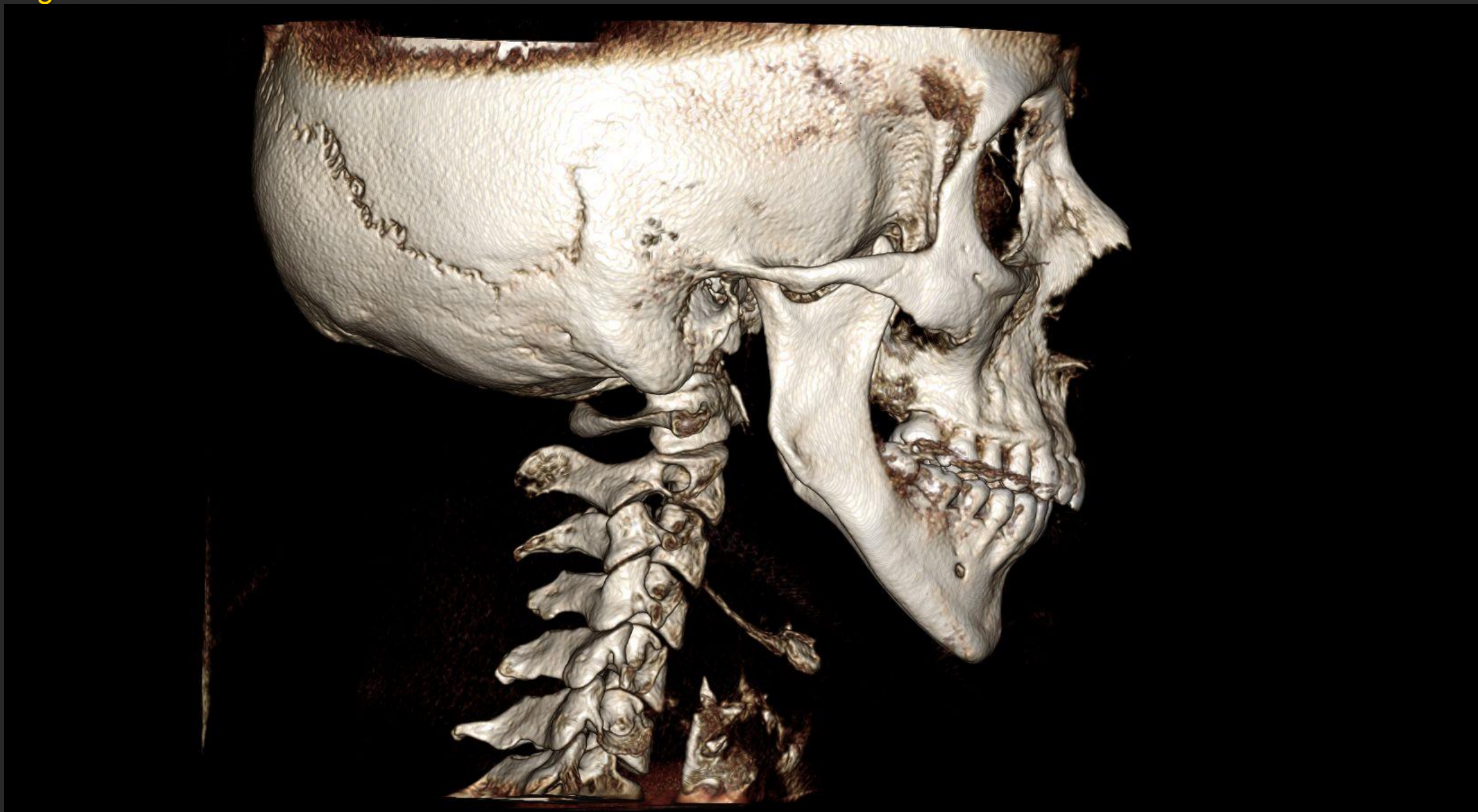


Anterior Profile: Anna Minnema 03/08/2022

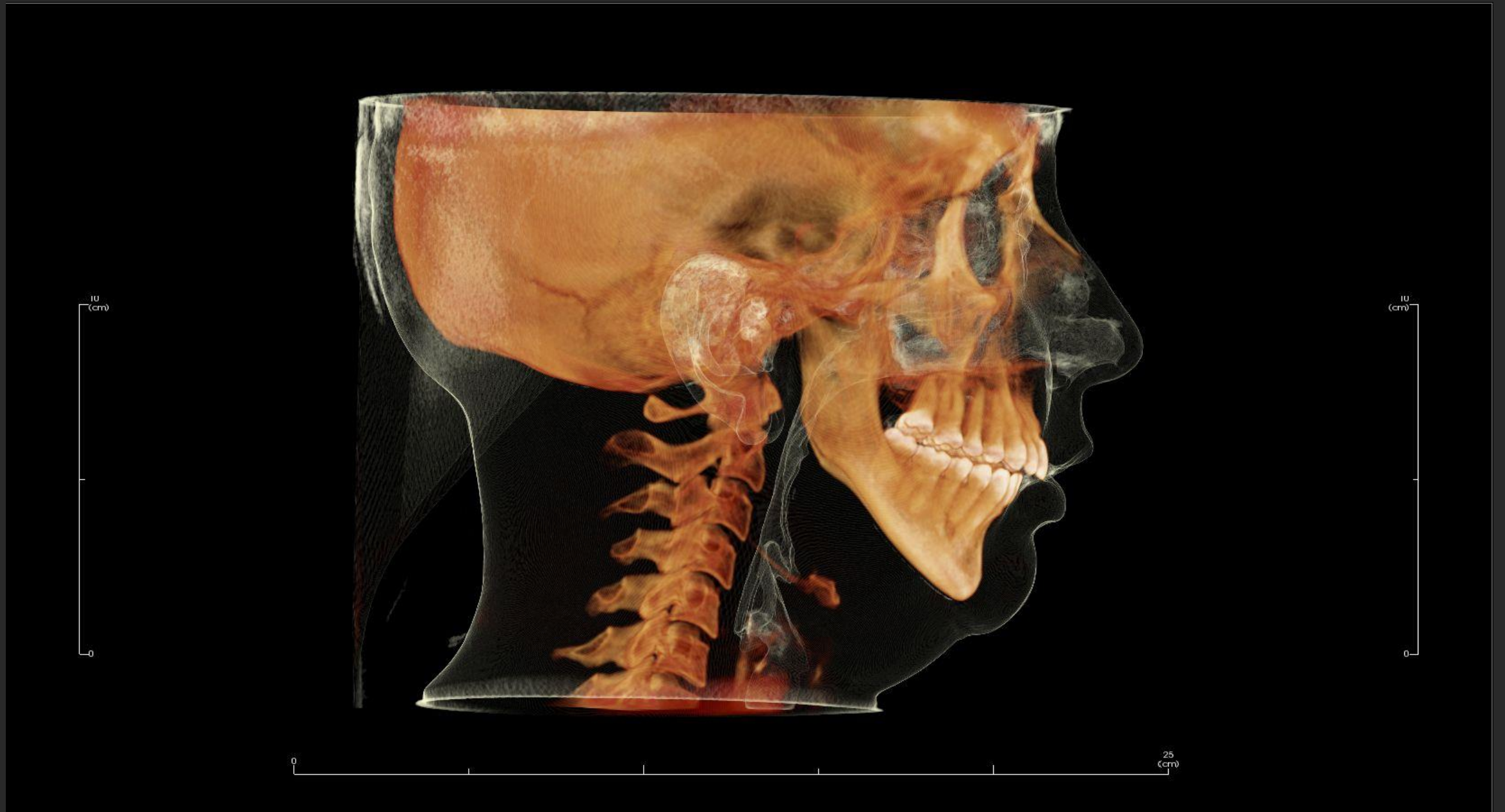




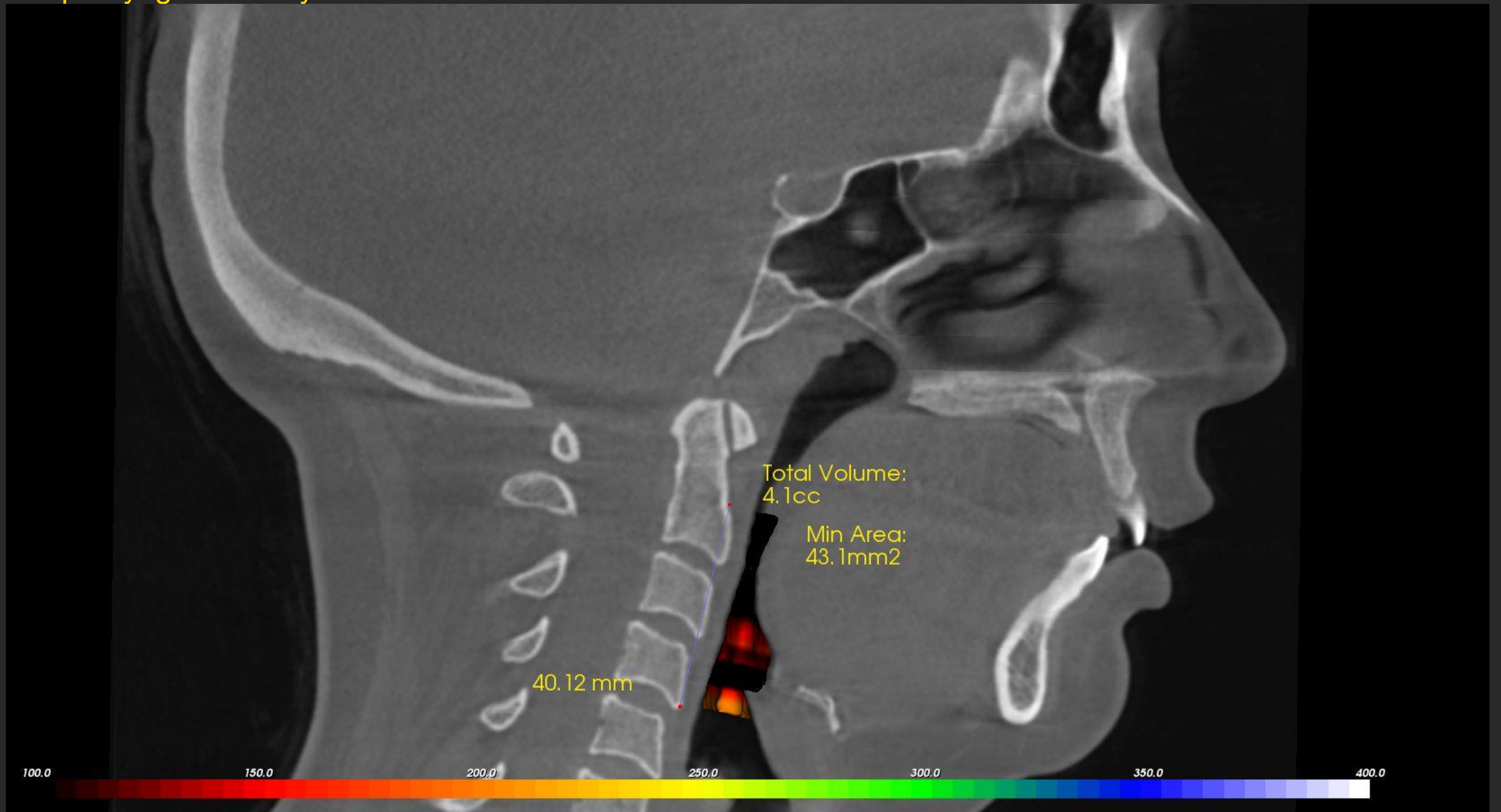
Right Profile: Anna Minnema 03/08/2022



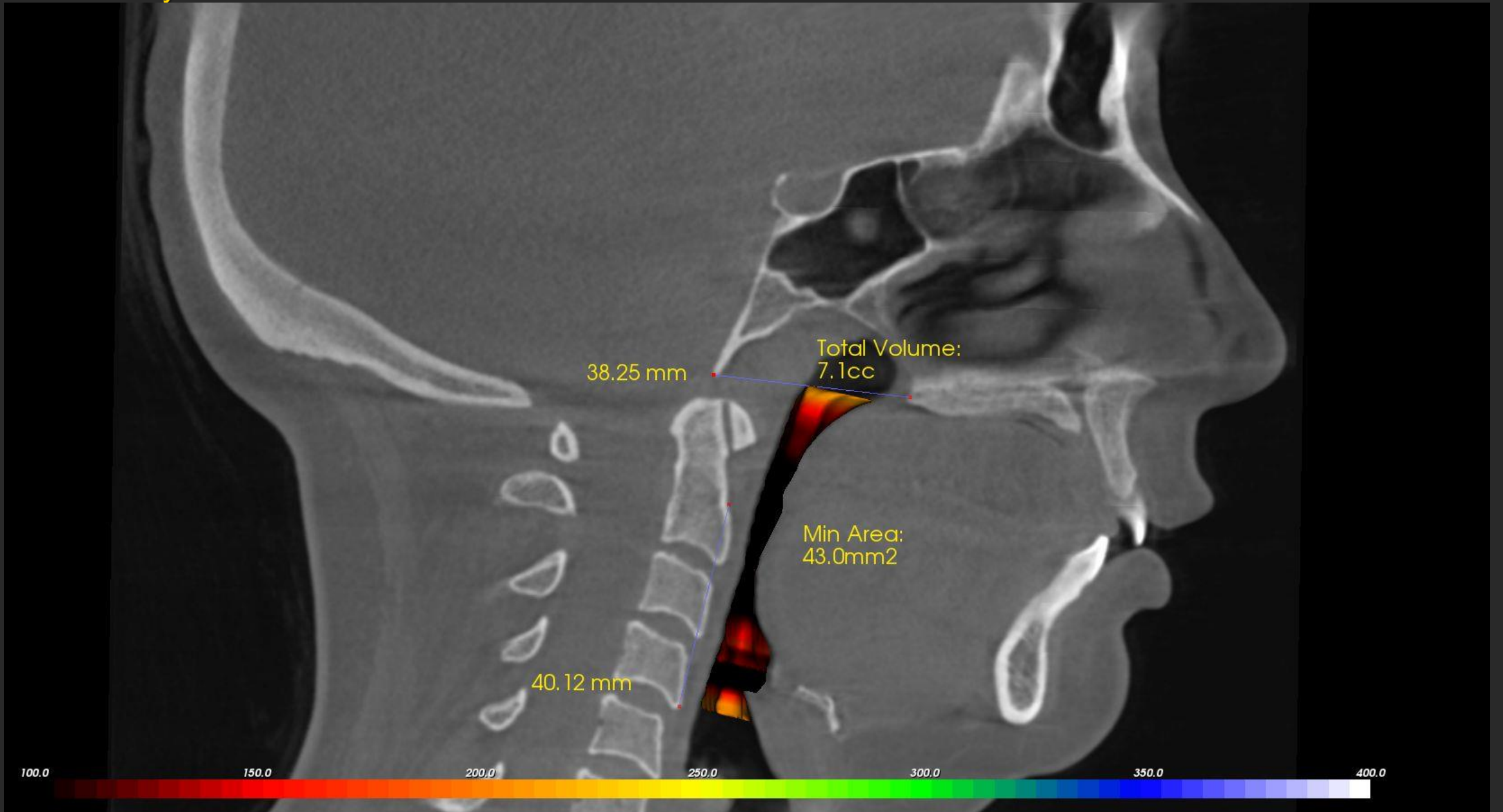
Soft Tissue Profile: Anna Minnema 03/08/2022



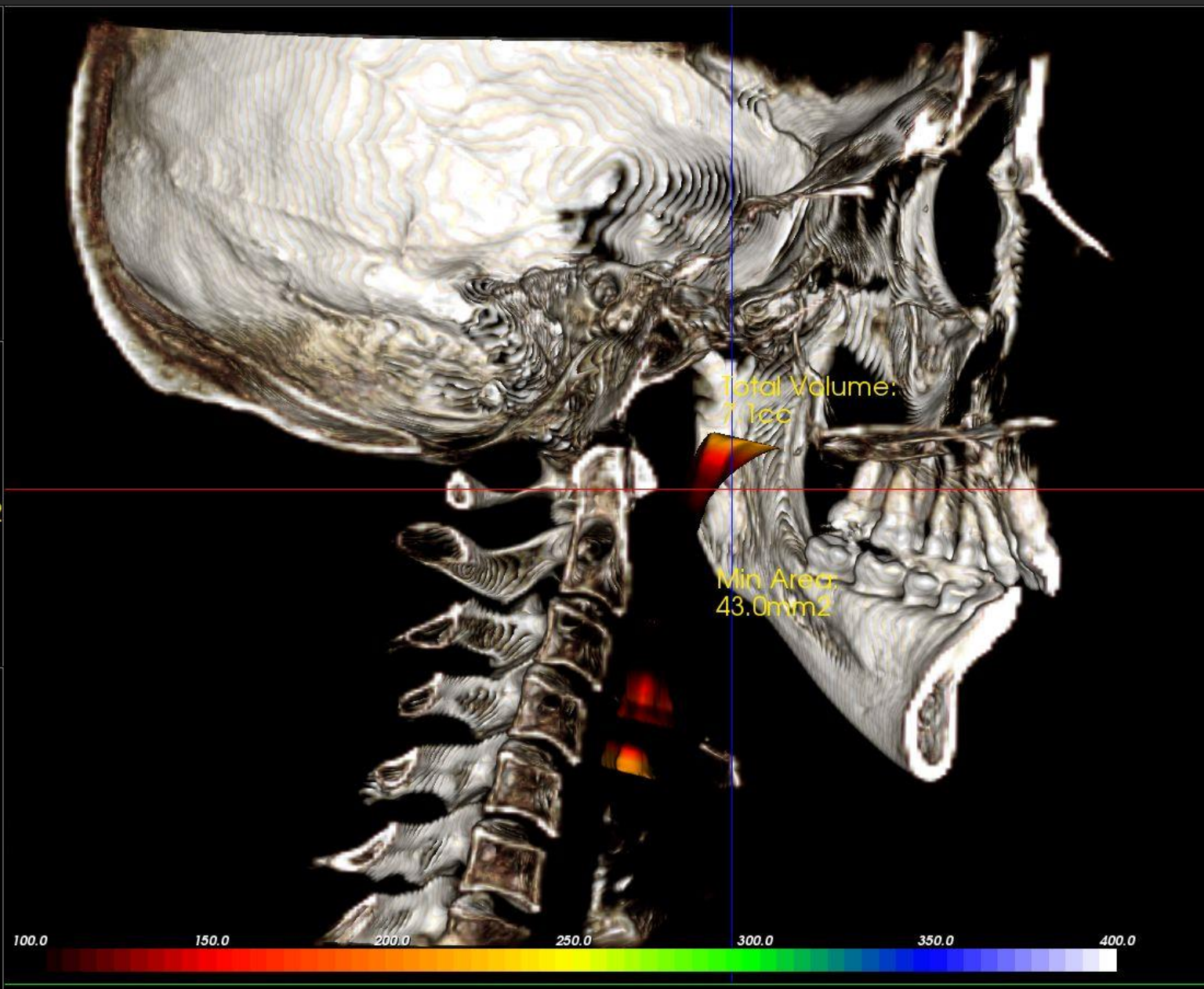
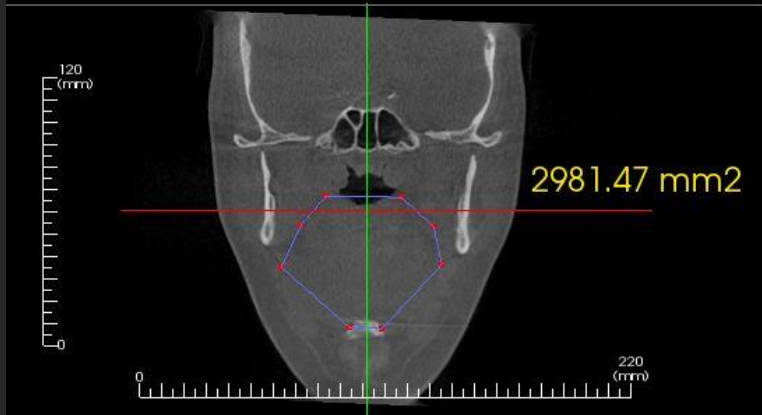
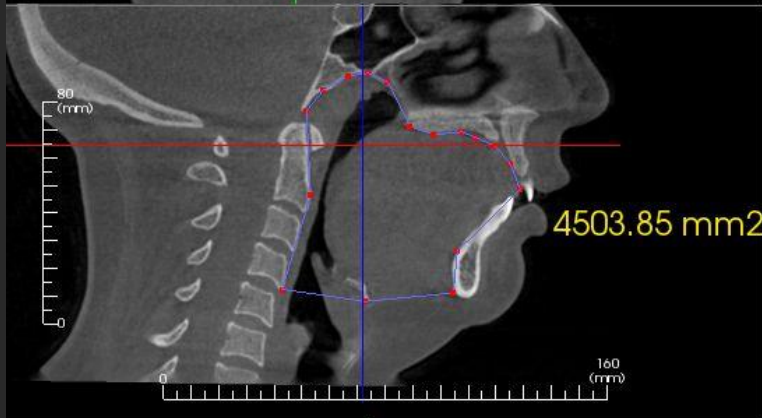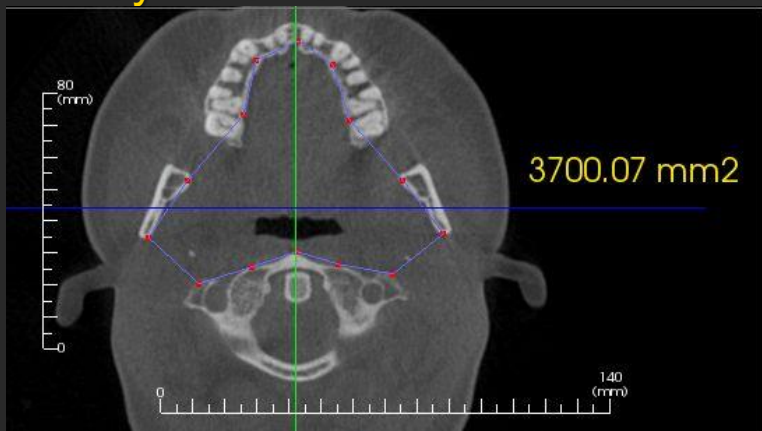
Oropharyngeal Airway: Anna Minnema 03/08/2022



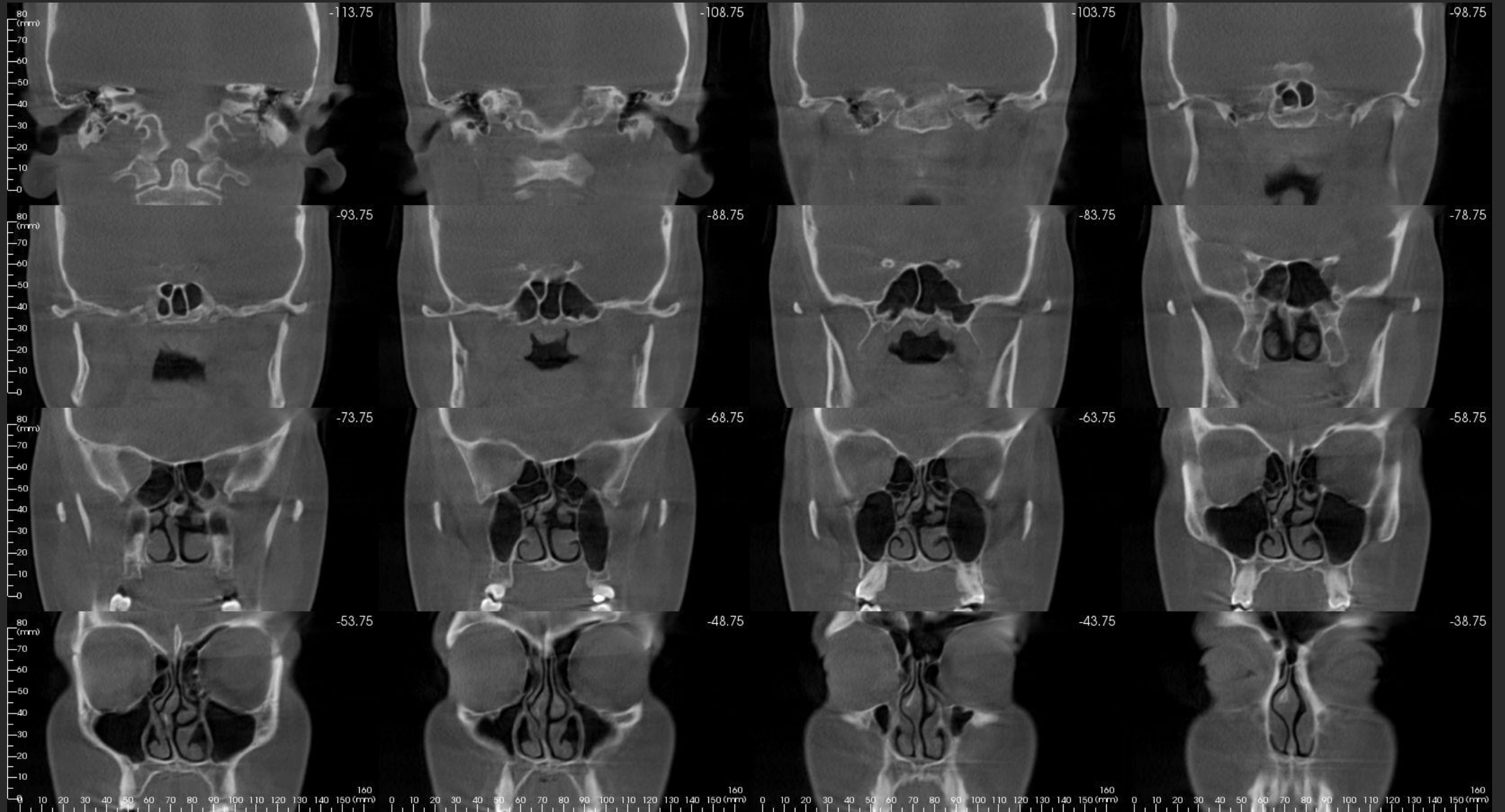
Total Airway: Anna Minnema 03/08/2022



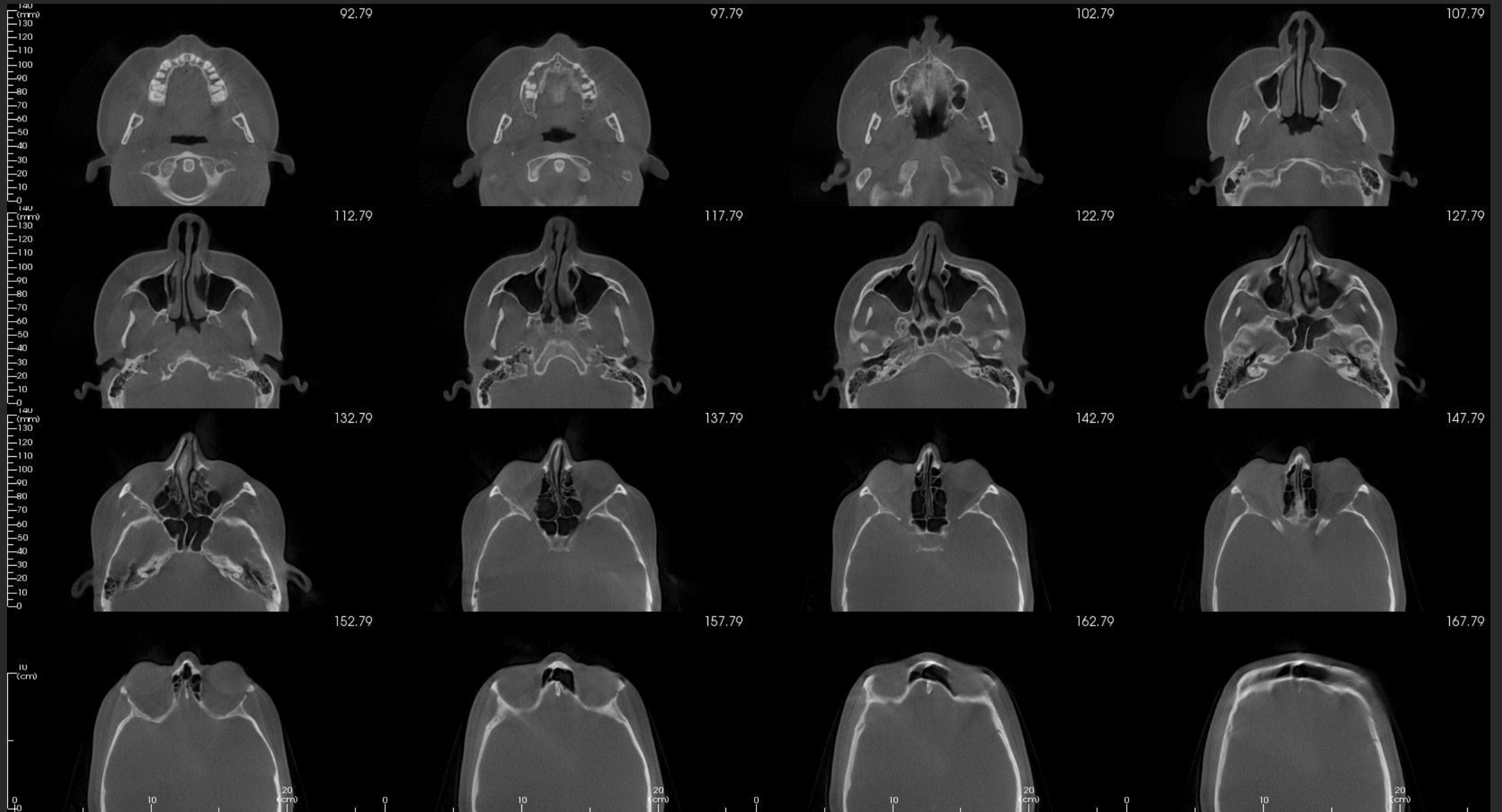
Airway Volumes: Anna Minnema 03/08/2022



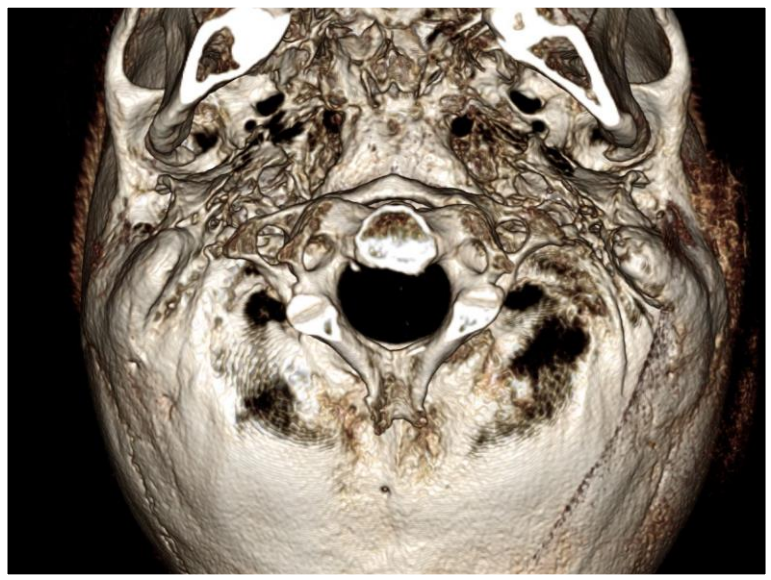
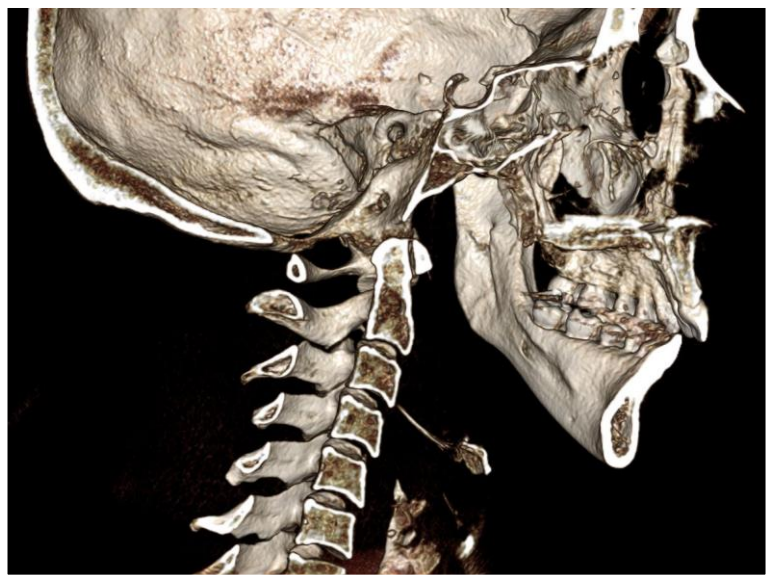
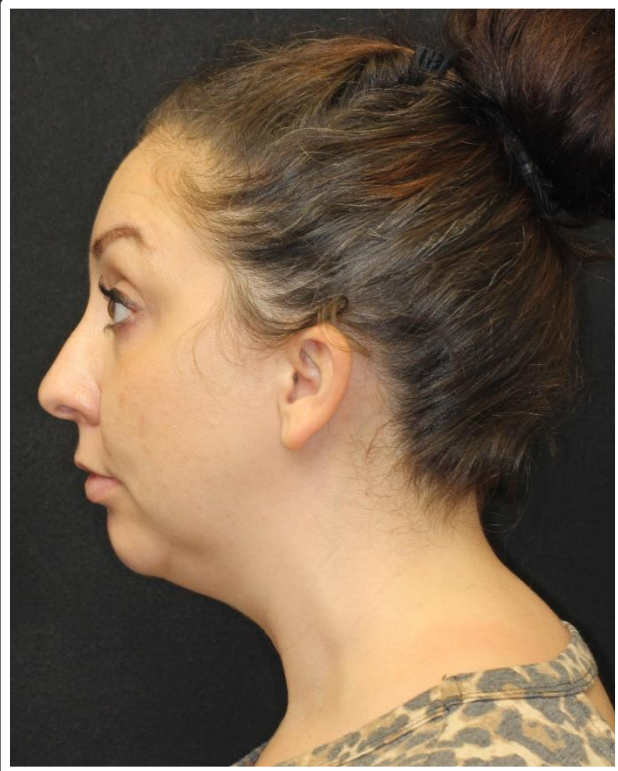
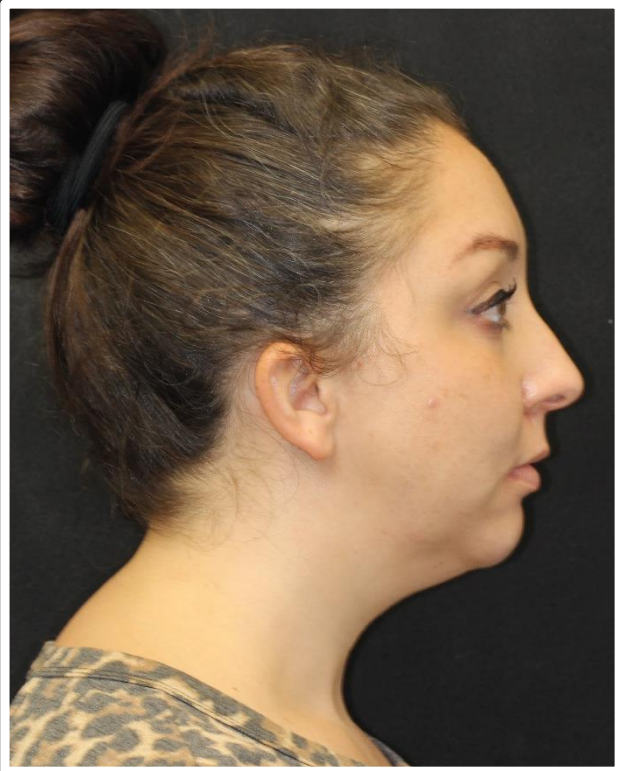Sinus Coronal: Anna Minnema 03/08/2022

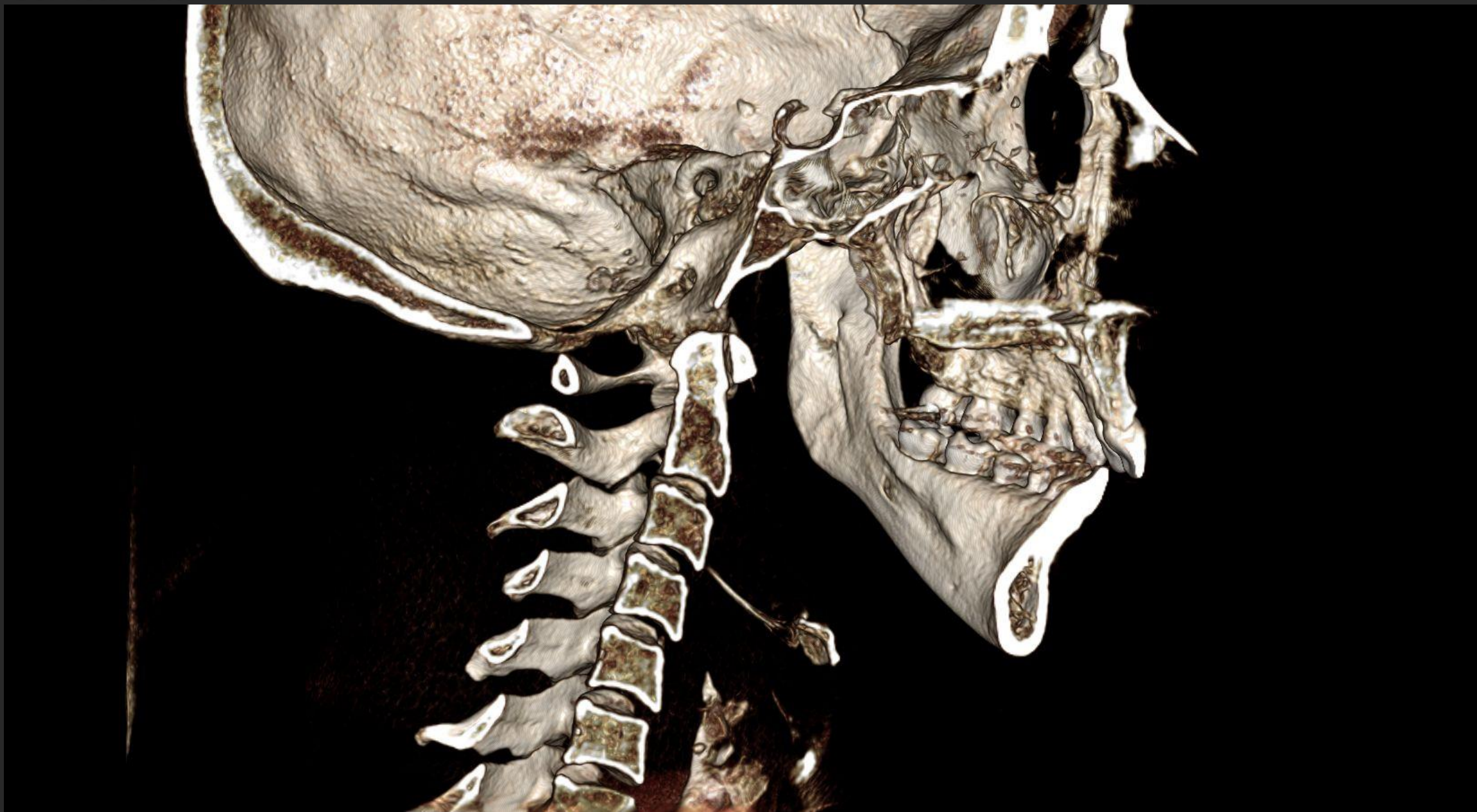


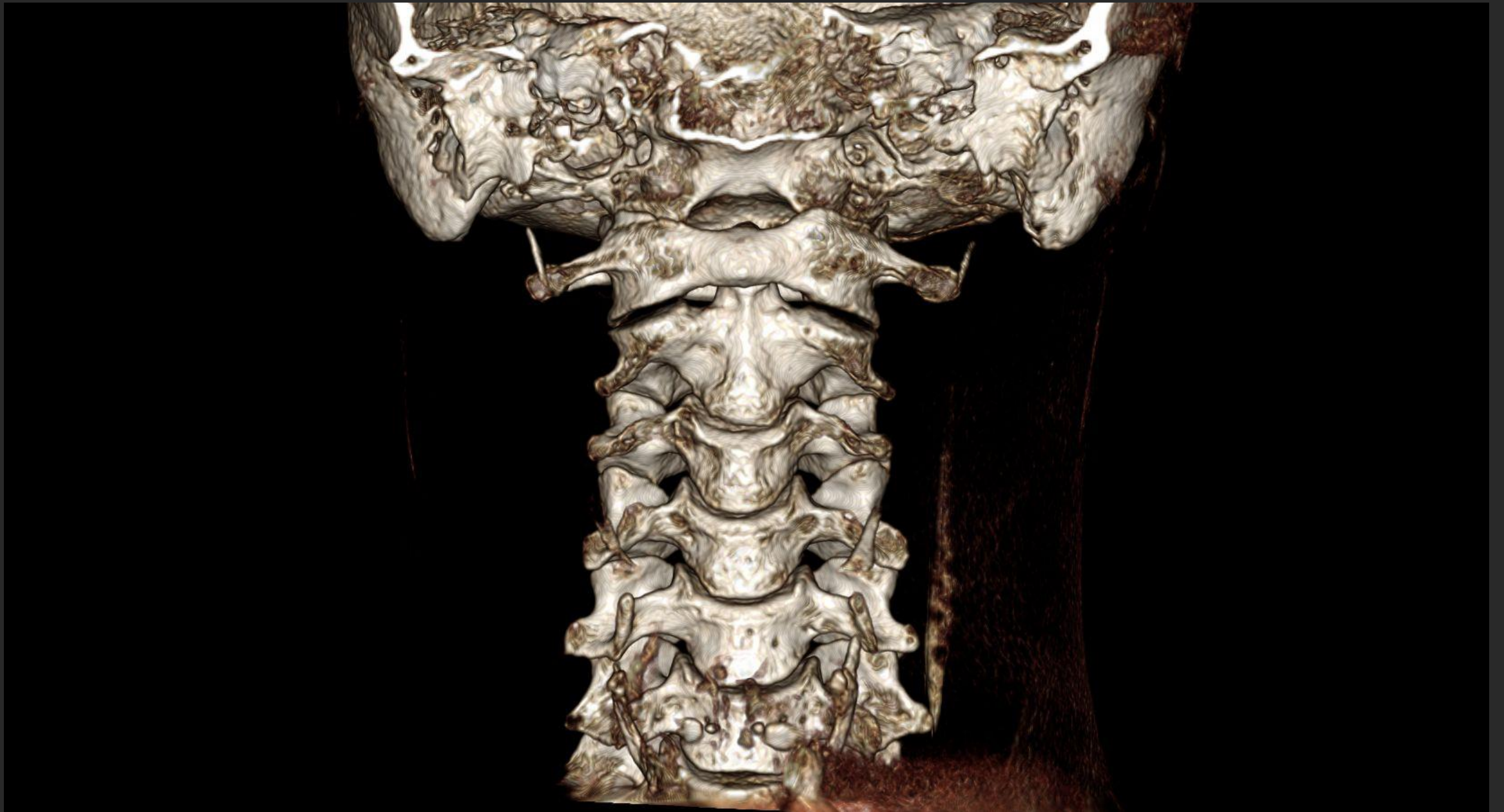Sinus Axial: Anna Minnema 03/08/2022



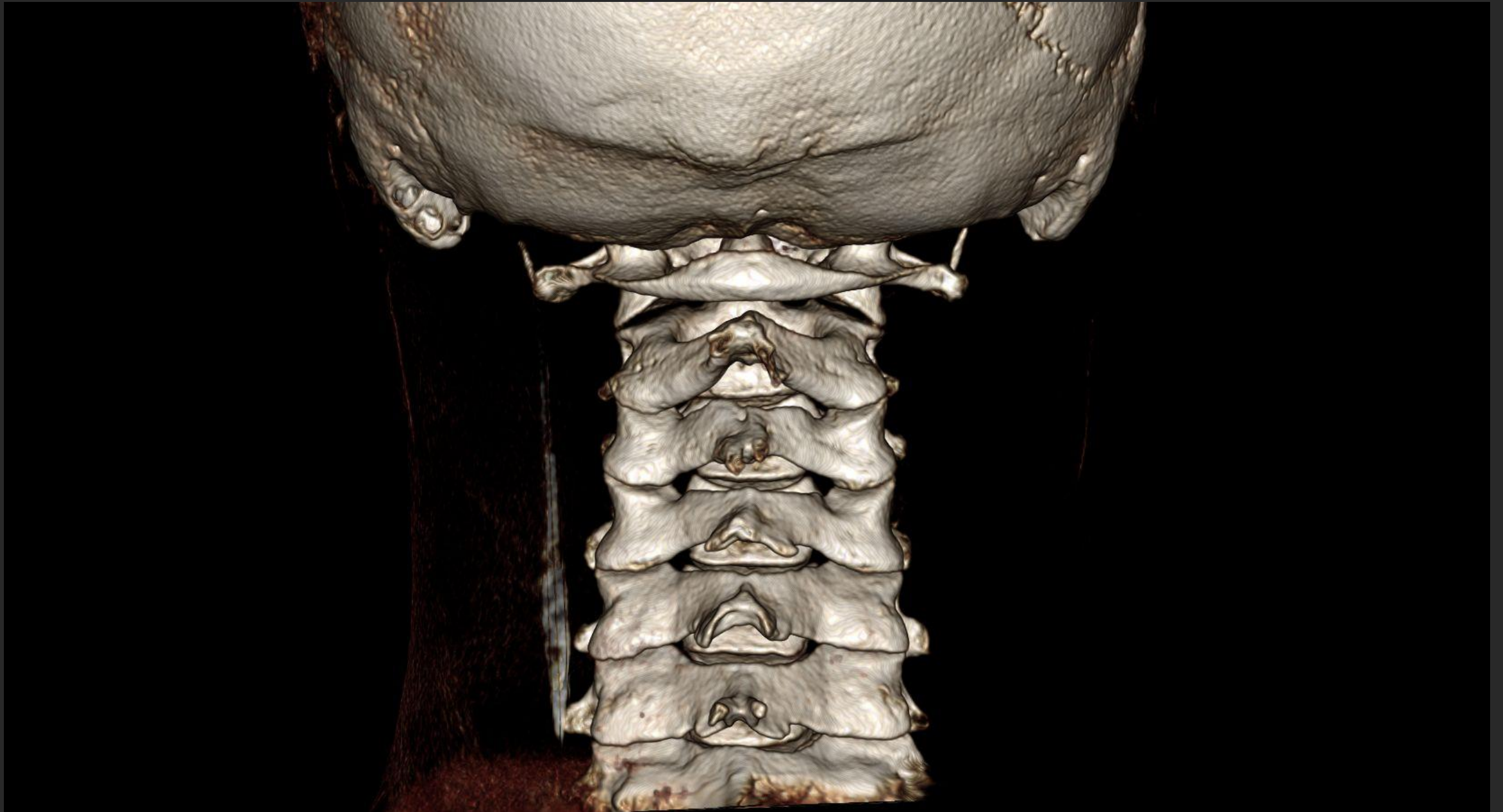
Initial Evaluation Cervical Assessment: Anna Minnema 03/08/2022

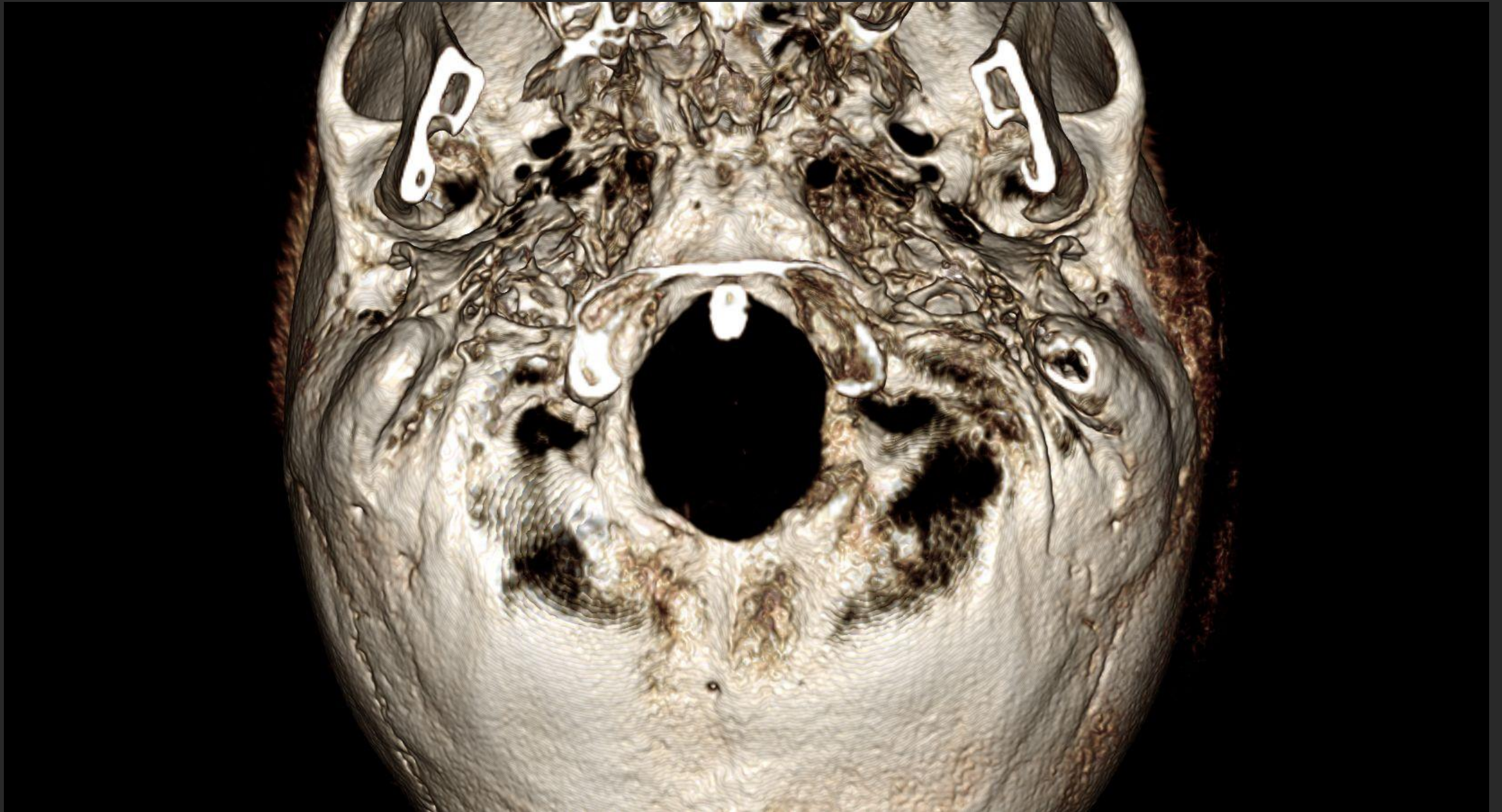


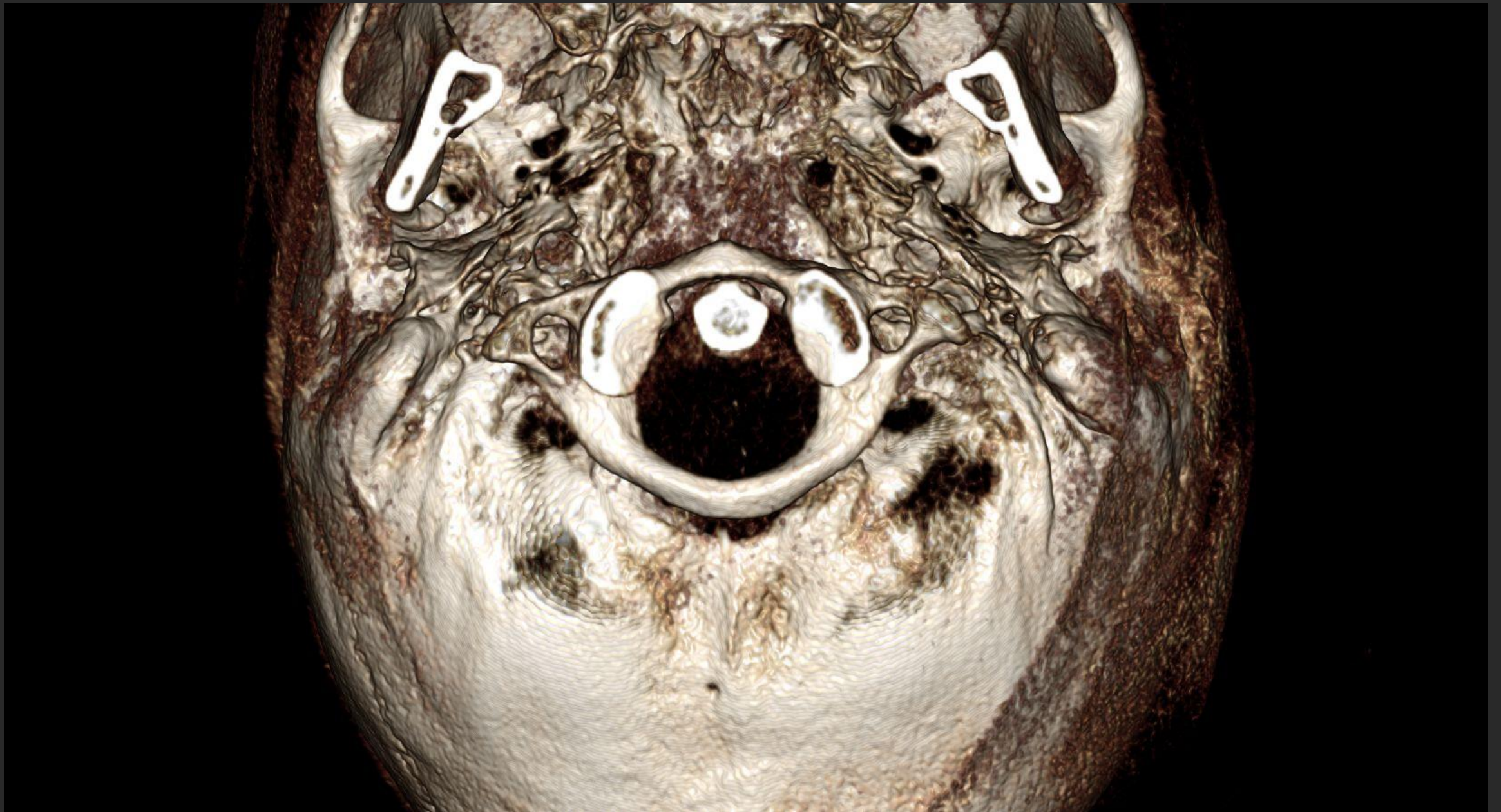


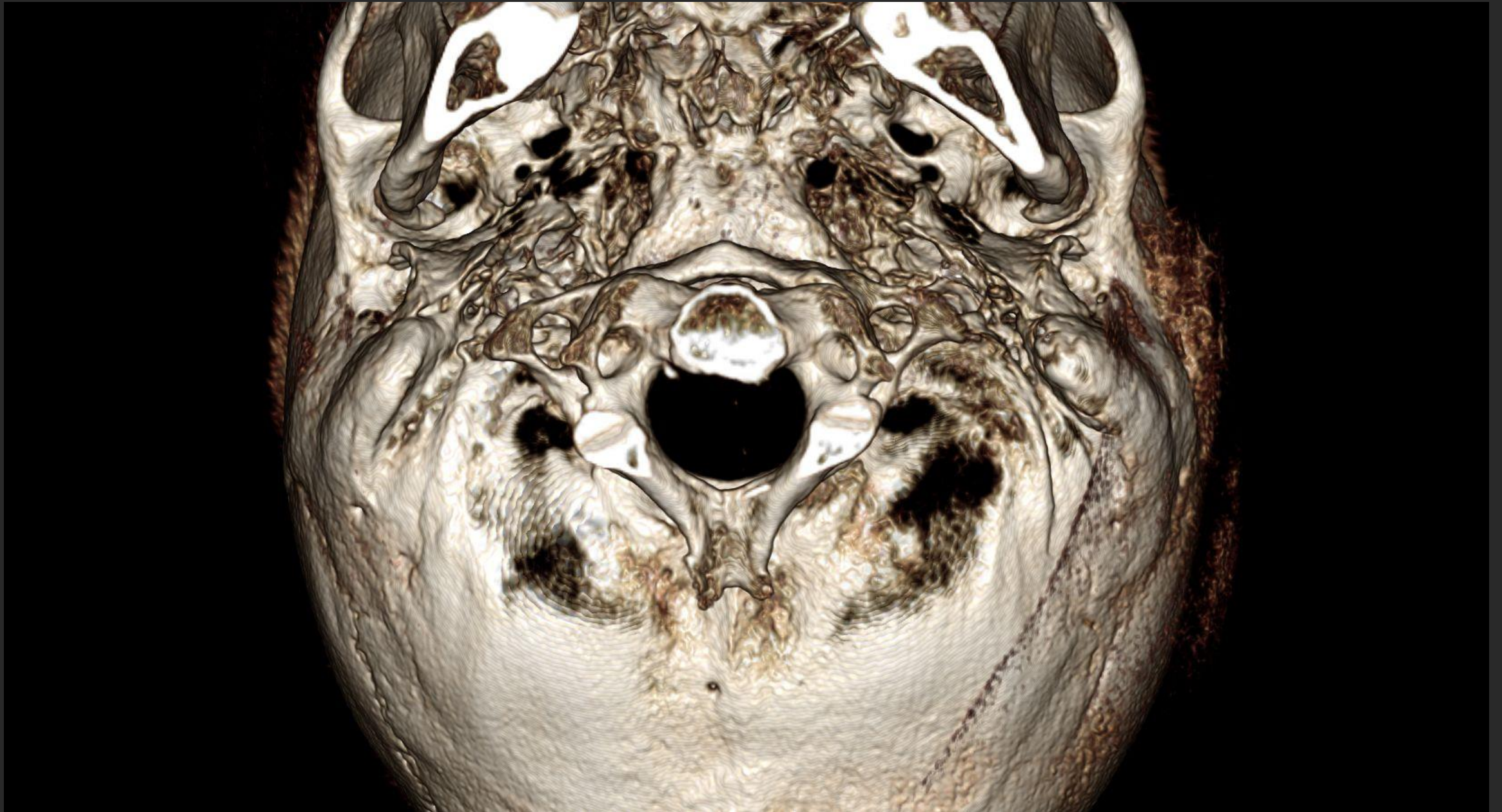
Cervical Posterior: Anna Minnema 03/08/2022

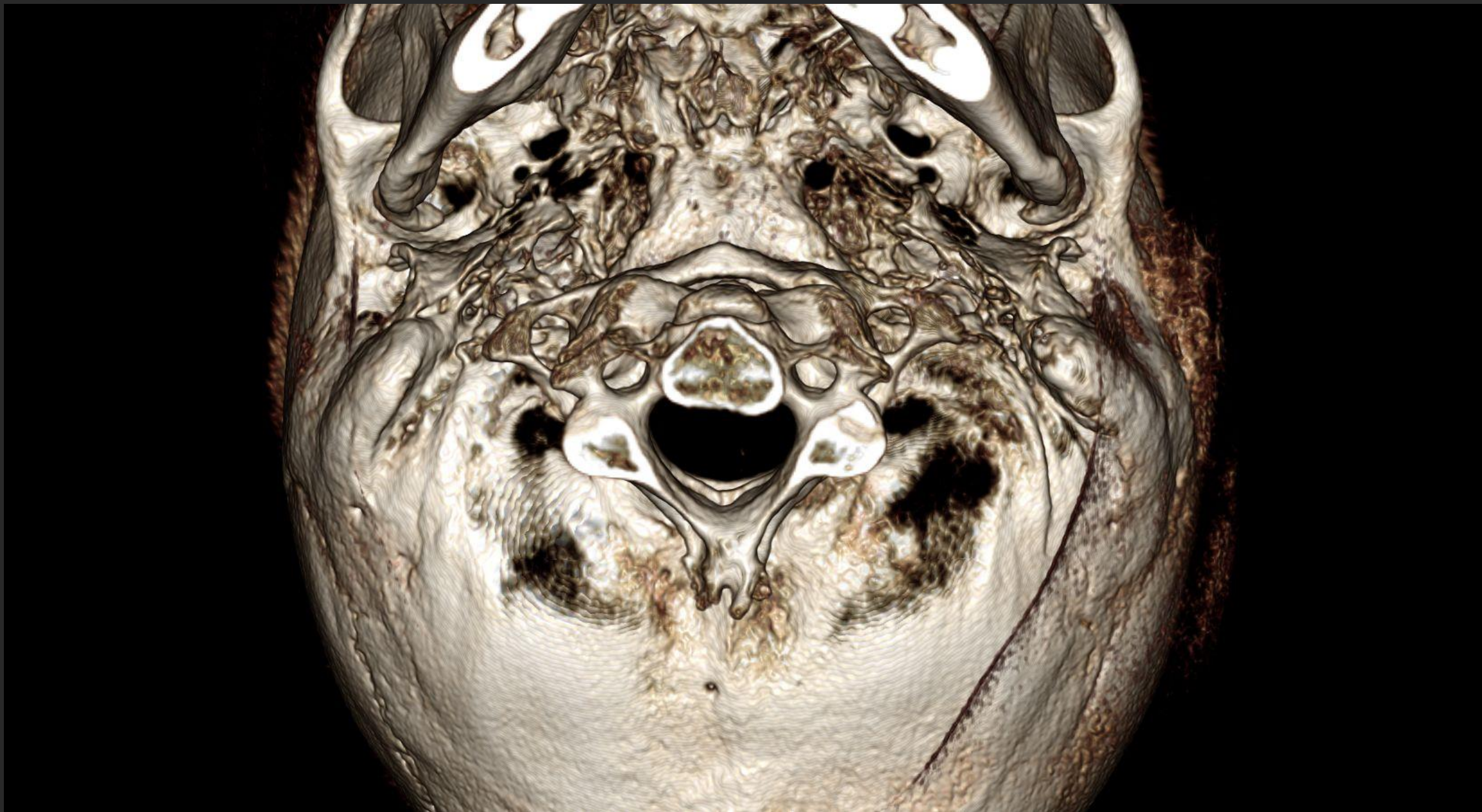




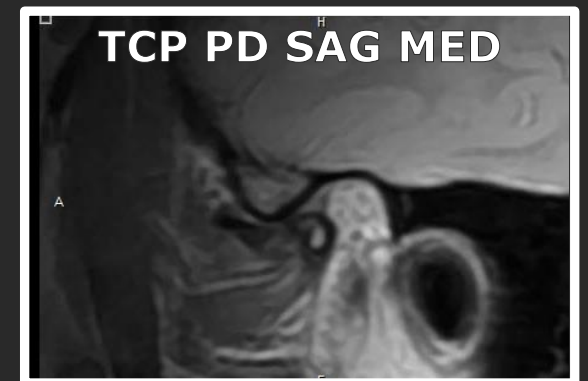
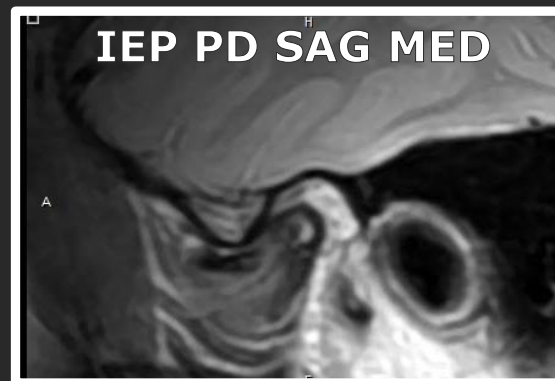
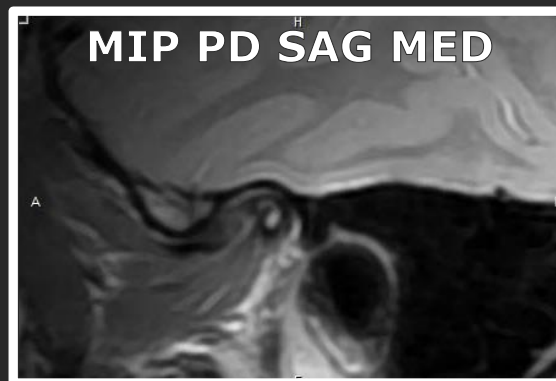
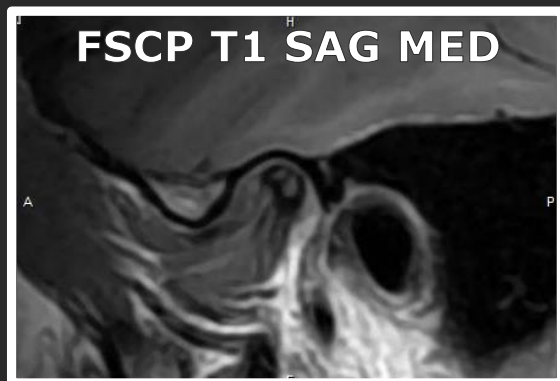
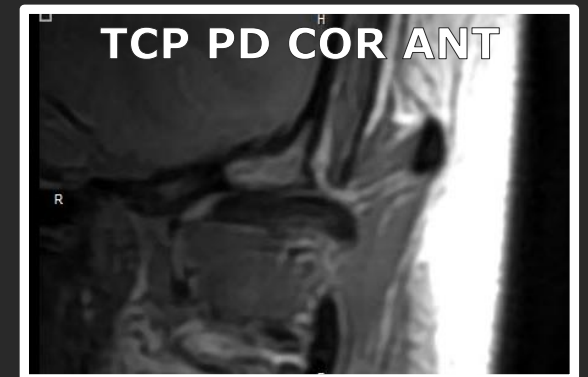
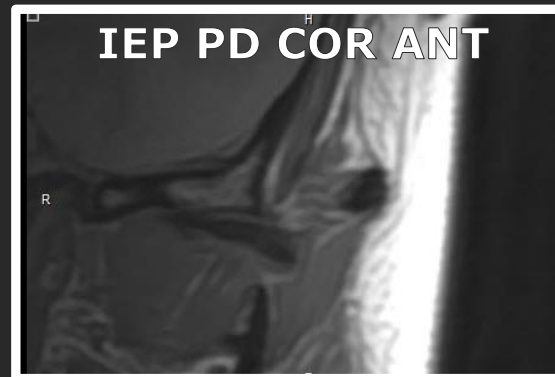
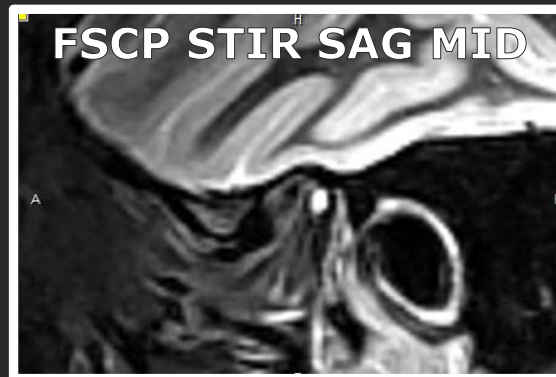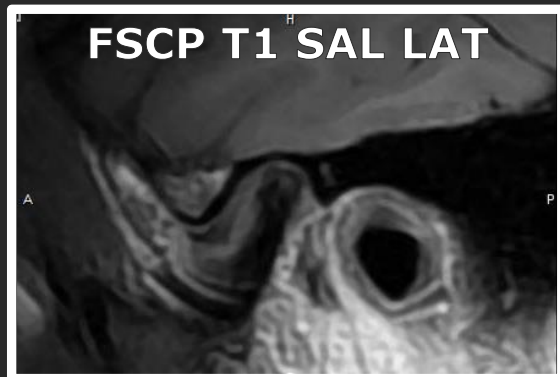
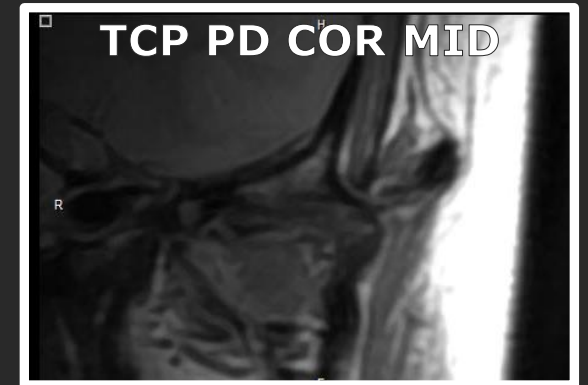
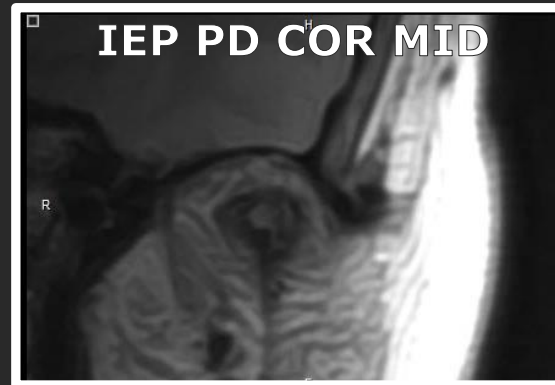
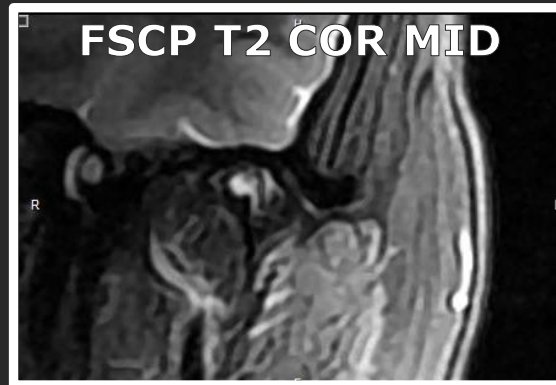

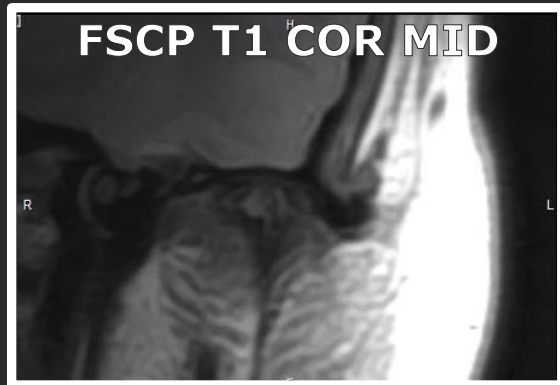
Axial C-2: Anna Minnema 03/08/2022

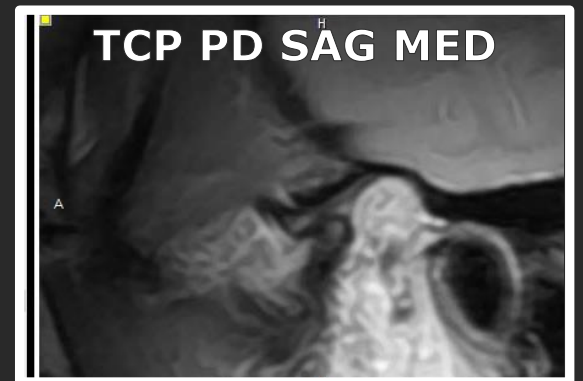
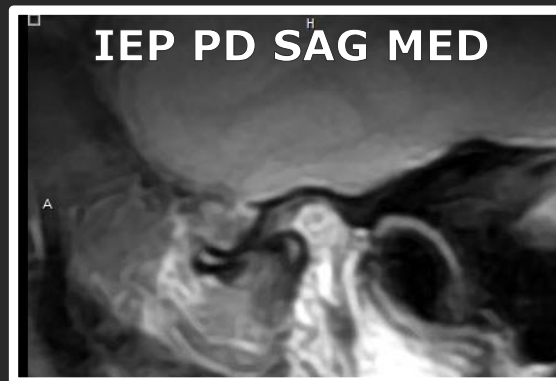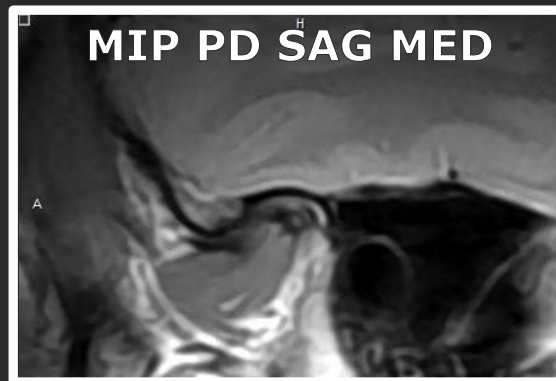
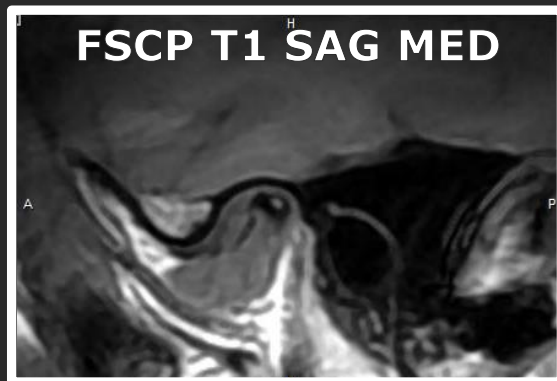
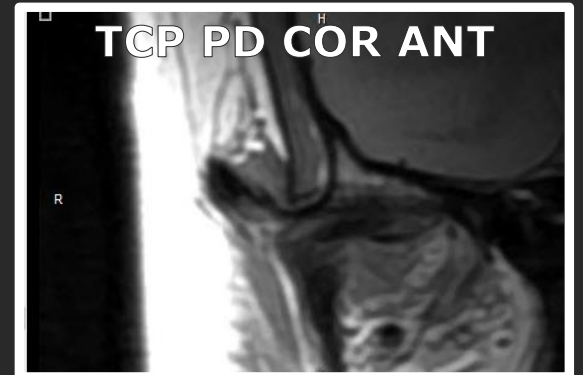
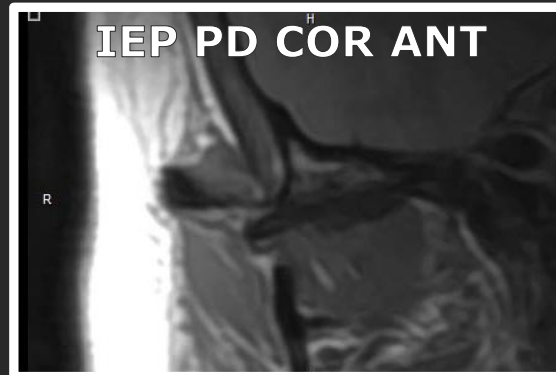
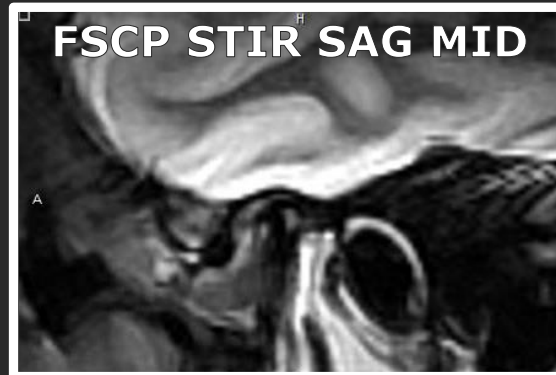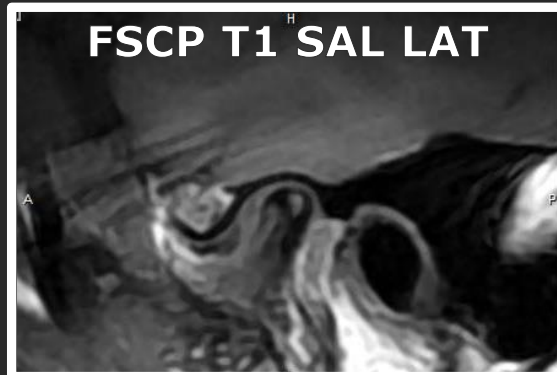
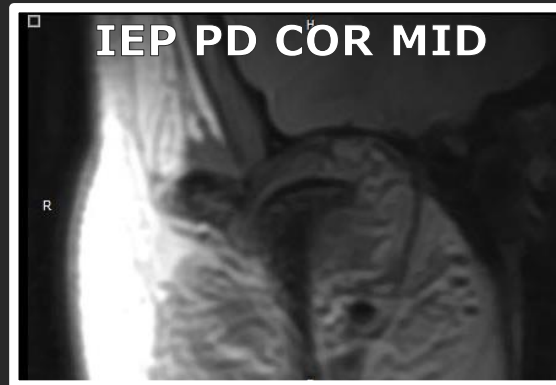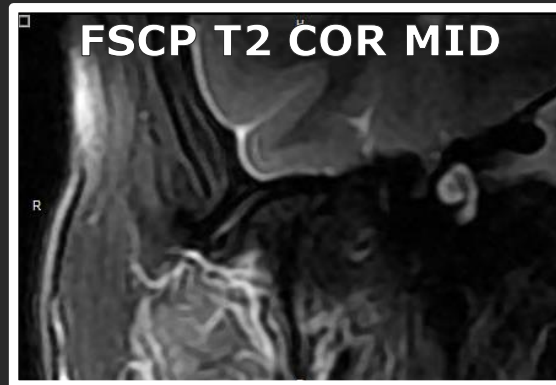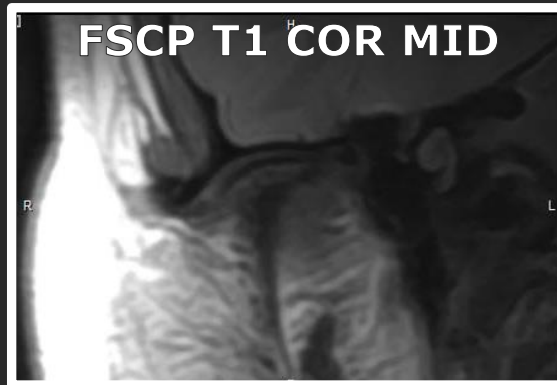




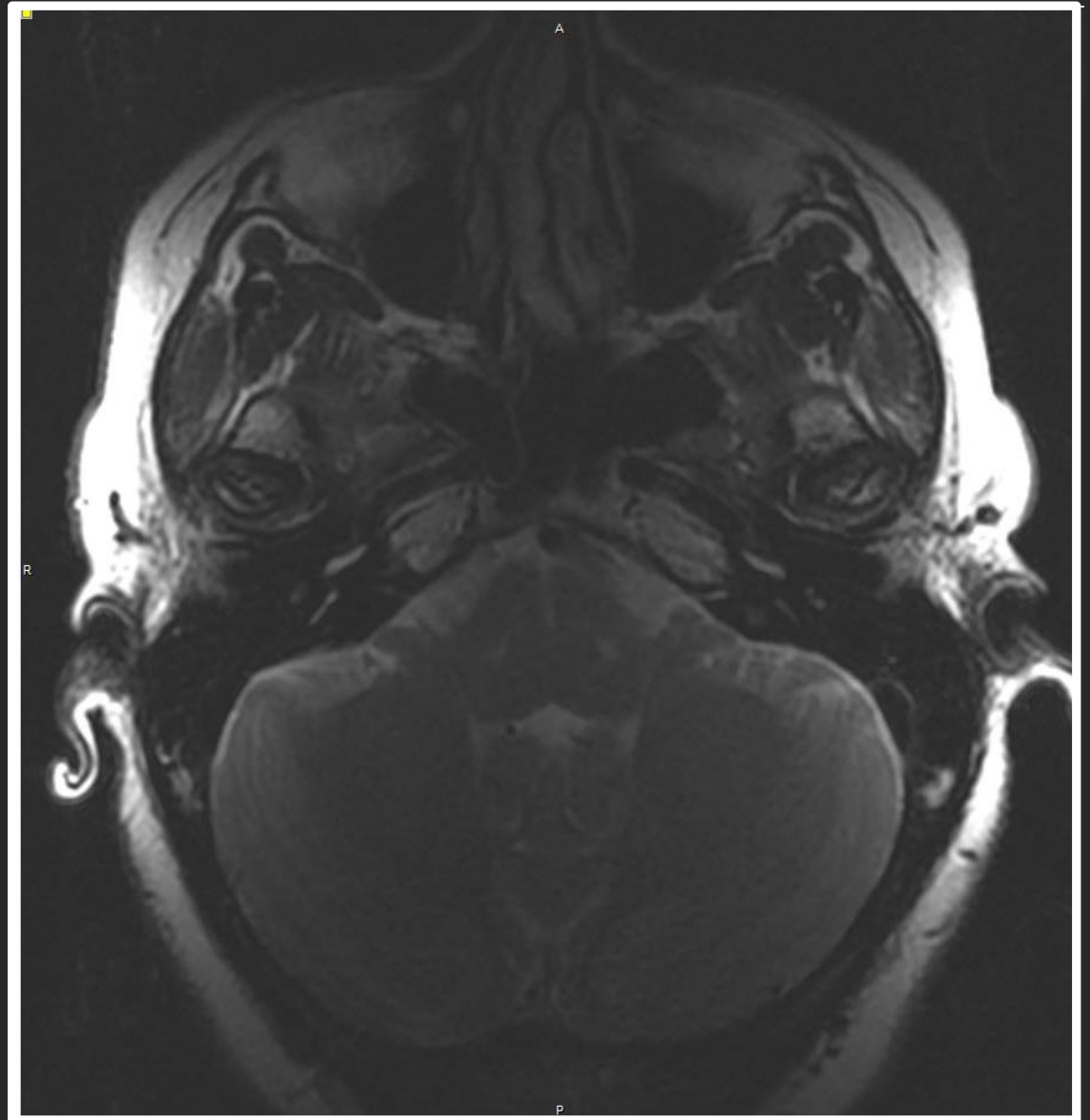
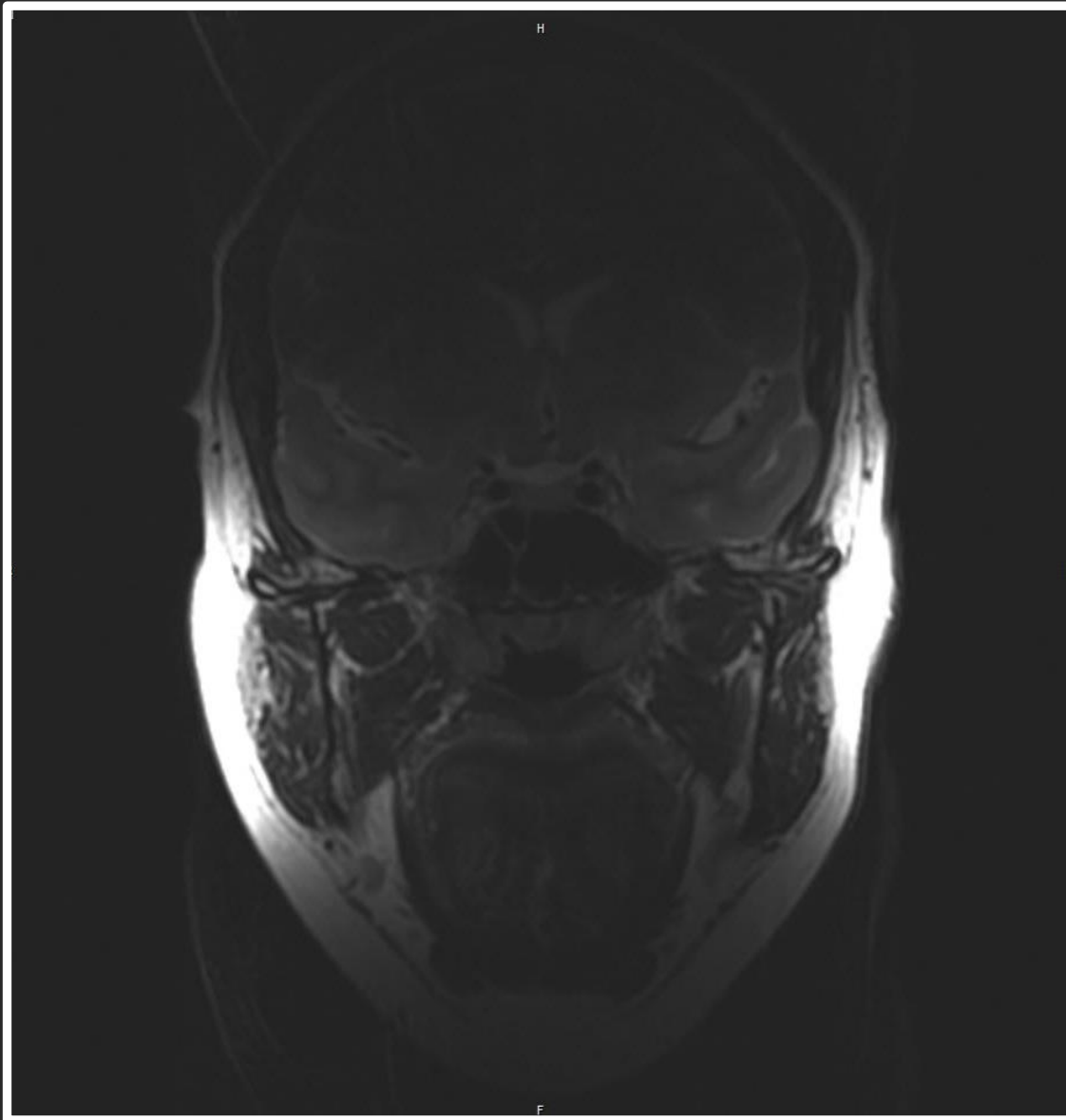
Initial Evaluation Left TMJ MRI: Anna Minnema 03/08/2022



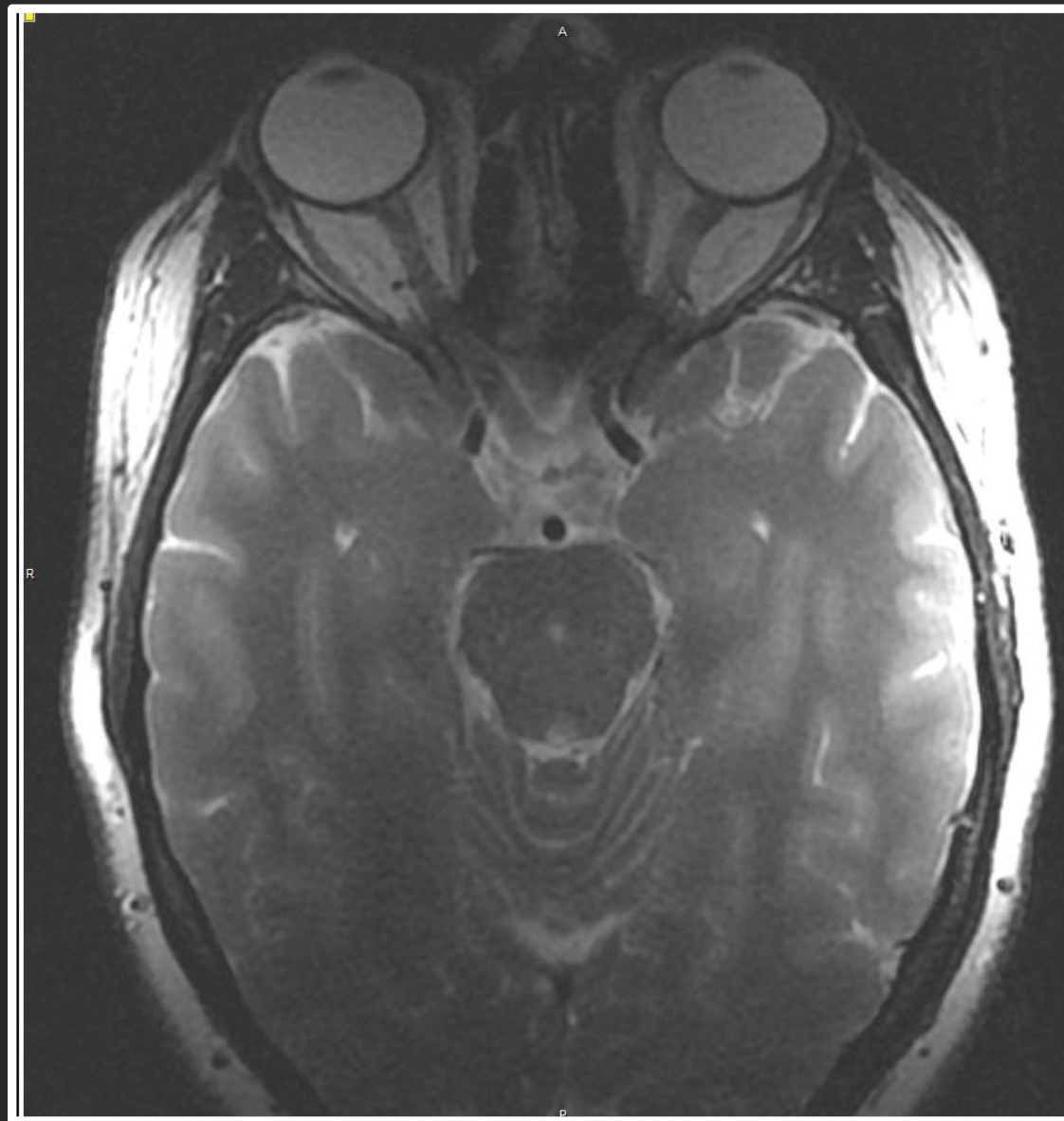
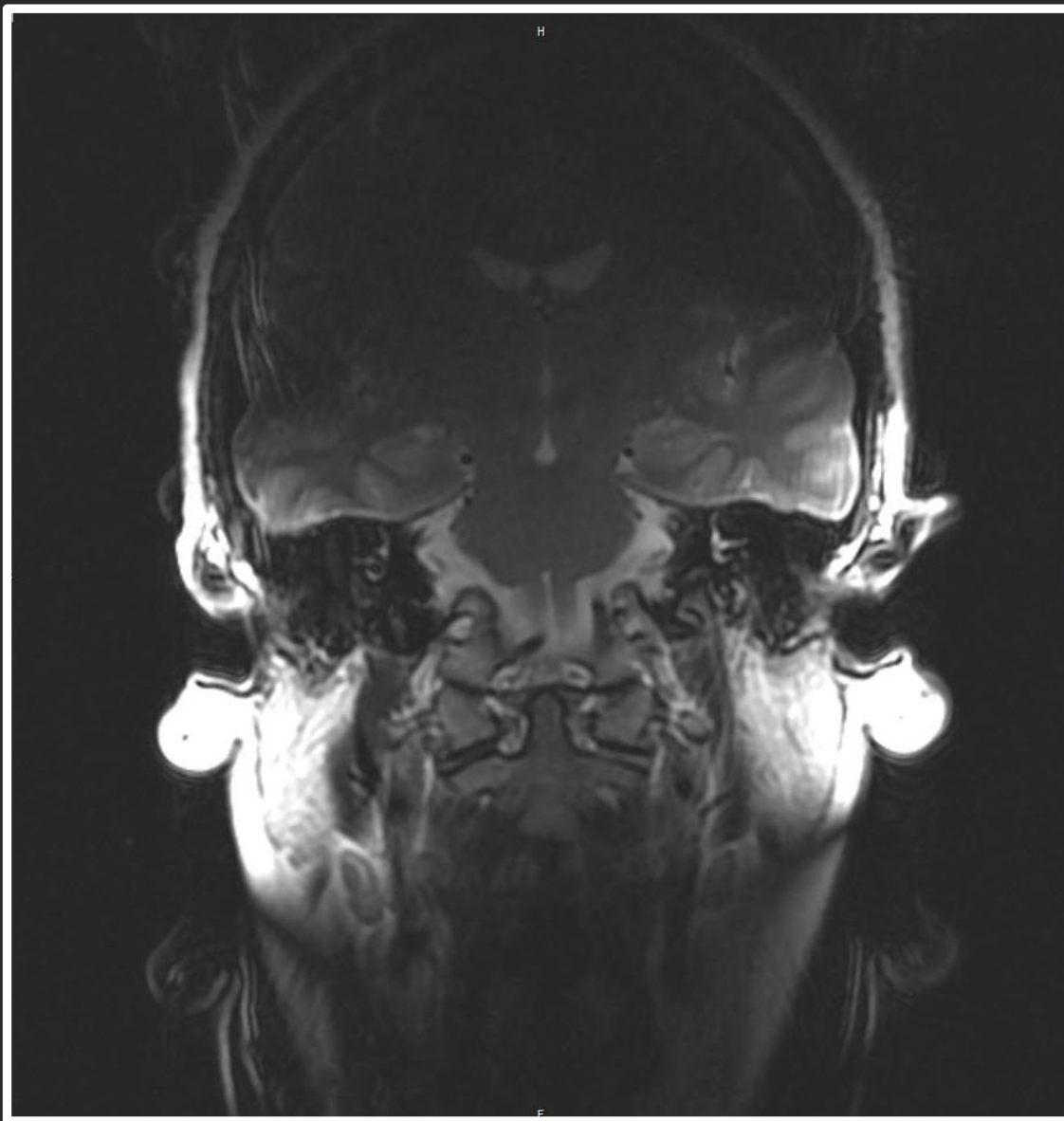
Initial Evaluation Right TMJ MRI: Anna Minnema 03/08/2022



Initial Evaluation TMJ MRI: Anna Minnema 03/08/2022



Initial Evaluation Brain MRI: Anna Minnema 03/08/2022



Initial Evaluation Parotids MRI: Anna Minnema 03/08/2022

